



(19) **United States**

(12) **Patent Application Publication**
Selzer et al.

(10) **Pub. No.: US 2004/0116813 A1**

(43) **Pub. Date: Jun. 17, 2004**

(54) **SPLIT-SCREEN DISPLAY SYSTEM AND
STANDARDIZED METHODS FOR
ULTRASOUND IMAGE ACQUISITION AND
MULTI-FRAME DATA PROCESSING**

(57) **ABSTRACT**

(76) Inventors: **Robert H. Selzer**, Los Angeles, CA
(US); **Howard N. Hodis**, South
Pasadena, CA (US)

Correspondence Address:
**STRADLING YOCCA CARLSON &
RAUTH, IP Department**
P.O. Box 7680
Newport Beach, CA 92660-6441 (US)

A standardized acquisition methodology assists operators to accurately replicate high resolution B-mode ultrasound images obtained over several spaced-apart examinations utilizing a split-screen display in which the arterial ultrasound image from an earlier examination is displayed on one side of the screen while a real-time "live" ultrasound image from a current examination is displayed next to the earlier image on the opposite side of the screen. By viewing both images, whether simultaneously or alternately, while manually adjusting the ultrasound transducer, an operator is able to bring into view the real-time image that best matches a selected image from the earlier ultrasound examination. Utilizing this methodology, dynamic material properties of arterial structures, such as IMT and diameter, are measured in a standard region over successive image frames. Each frame of the sequence has its echo edge boundaries automatically determined by using the immediately prior frame's true echo edge coordinates as initial boundary conditions. Computerized echo edge recognition and tracking over multiple successive image frames enhances measurement of arterial diameter and IMT and allows for improved vascular dimension measurements, including vascular stiffness and IMT determinations.


(21) Appl. No.: 10/319,411

(22) Filed: Dec. 13, 2002

Publication Classification

(51) Int. Cl.⁷ A61B 8/12

(52) U.S. Cl. 600/467



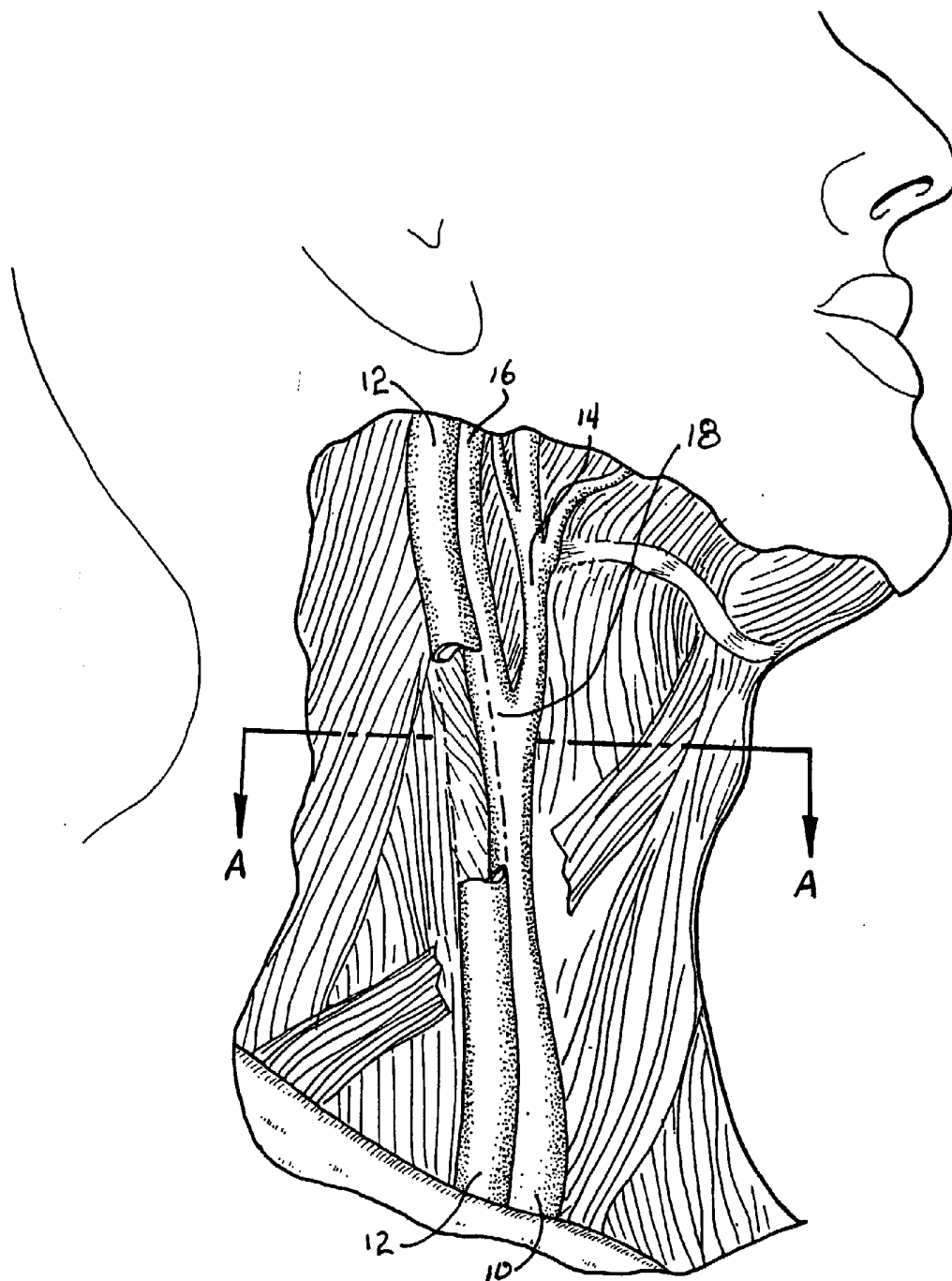


FIG. 1




FIG. 2

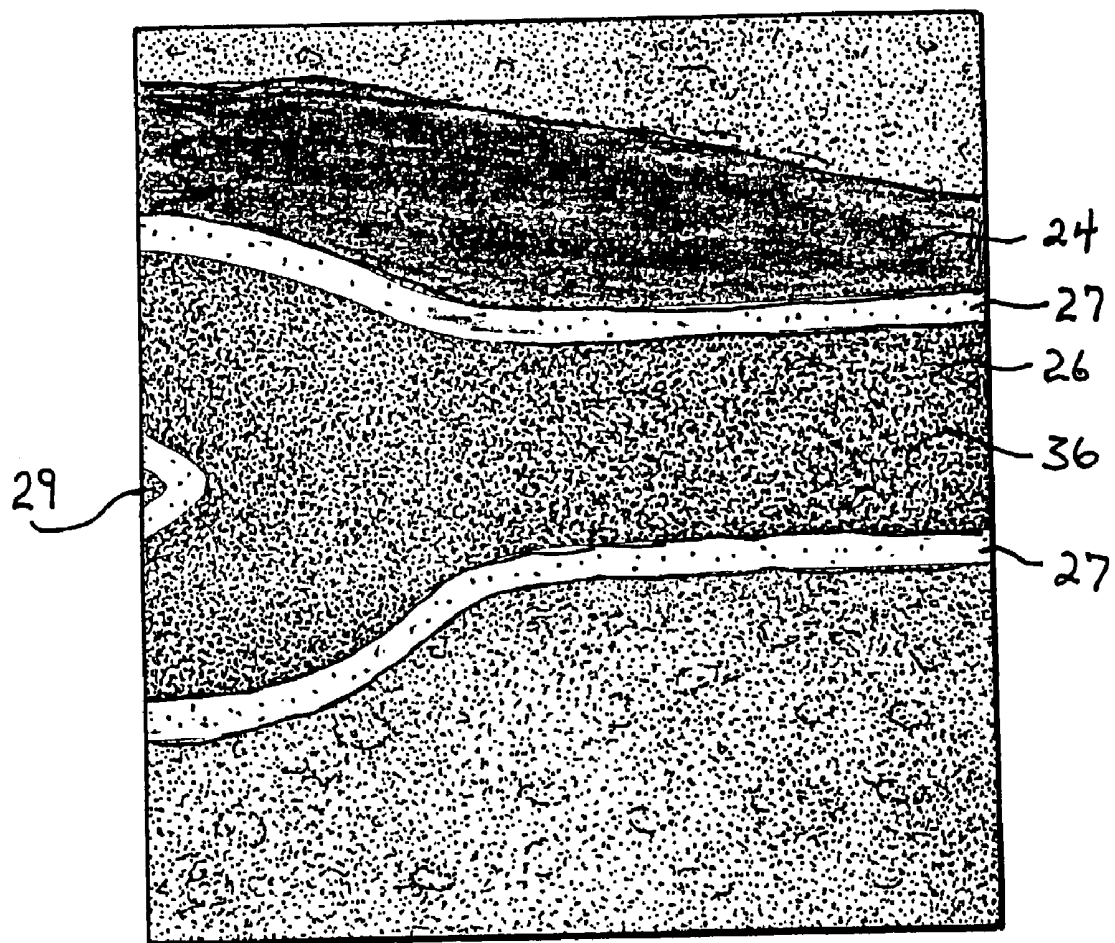


FIG. 3A

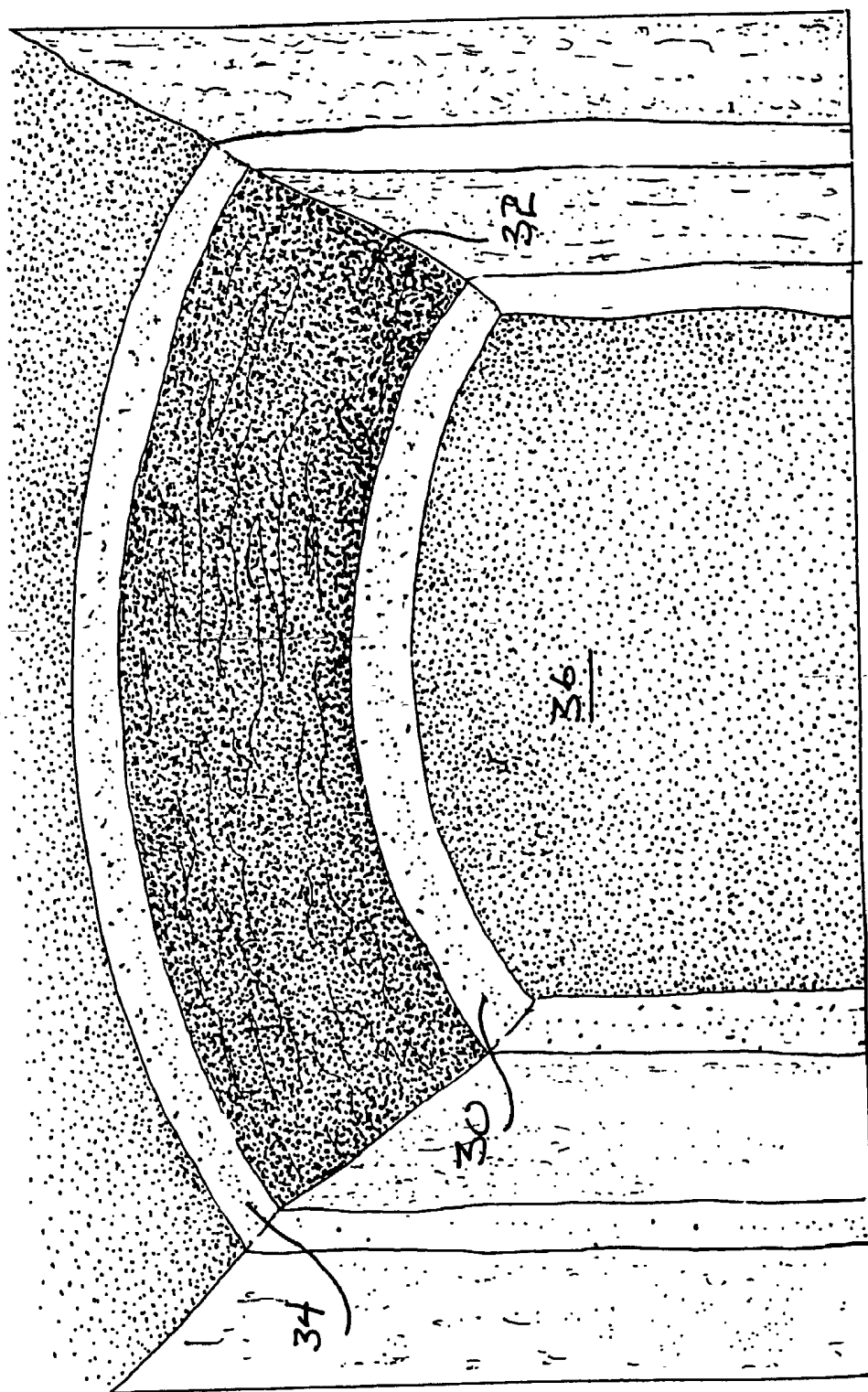


FIG. 3B

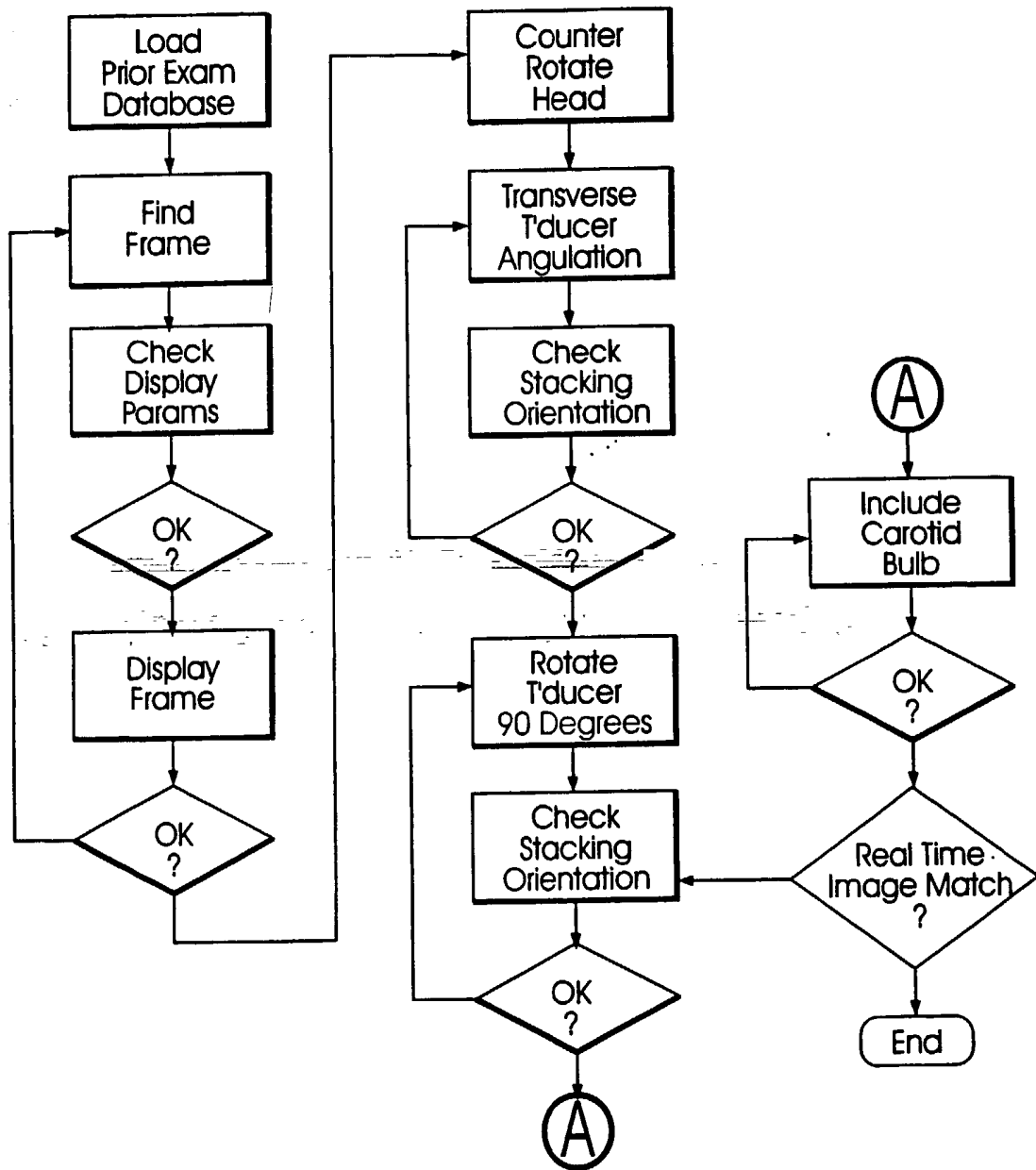


FIG. 4

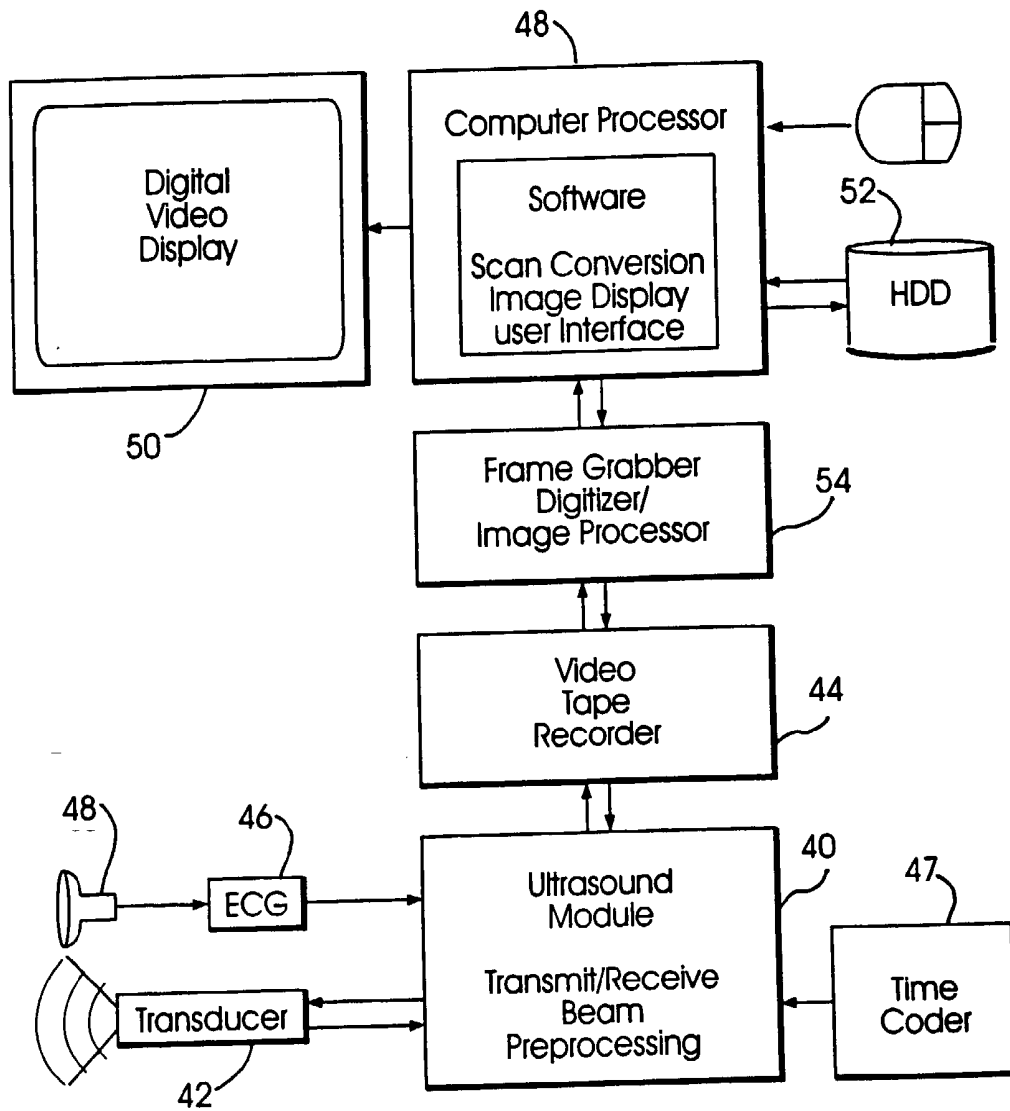


FIG. 5

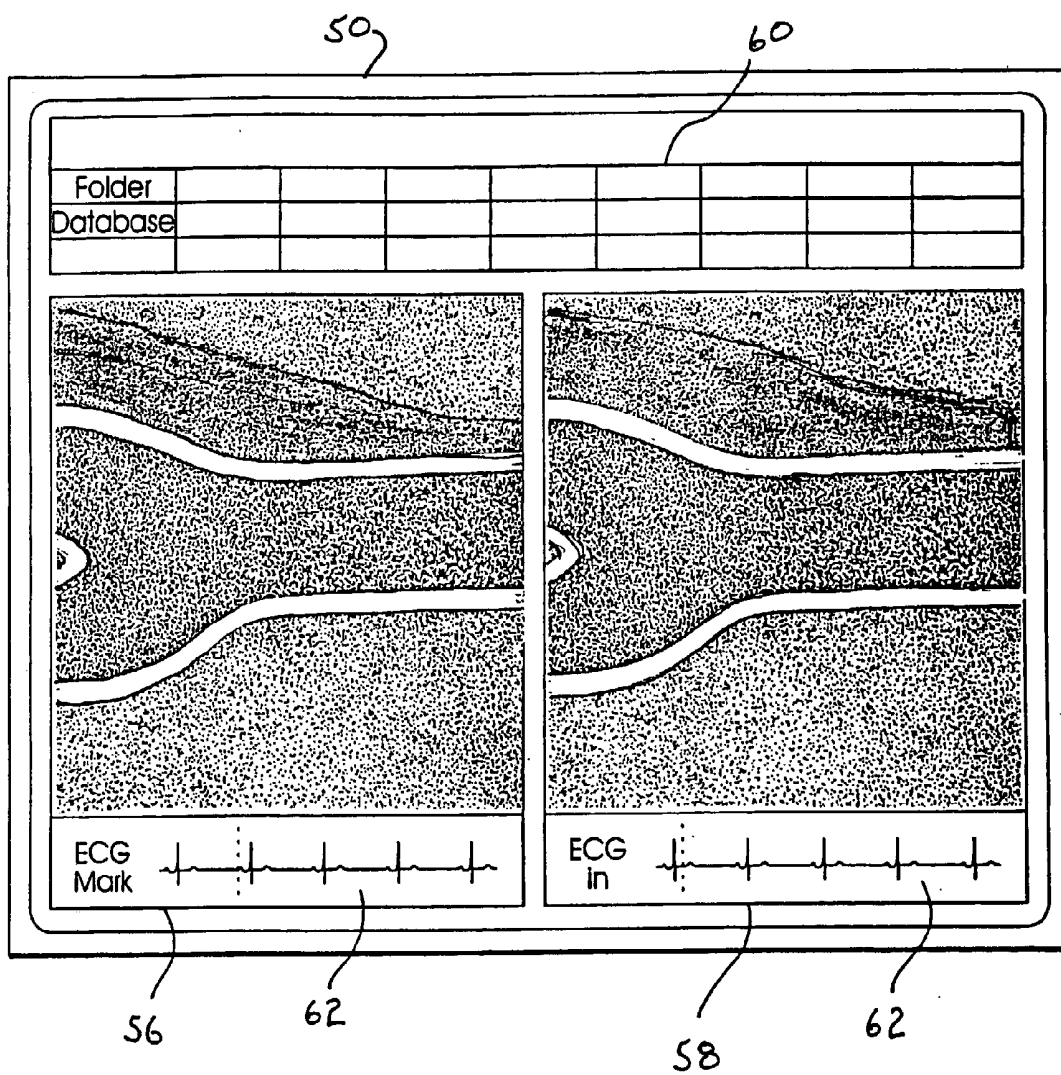


FIG. 6

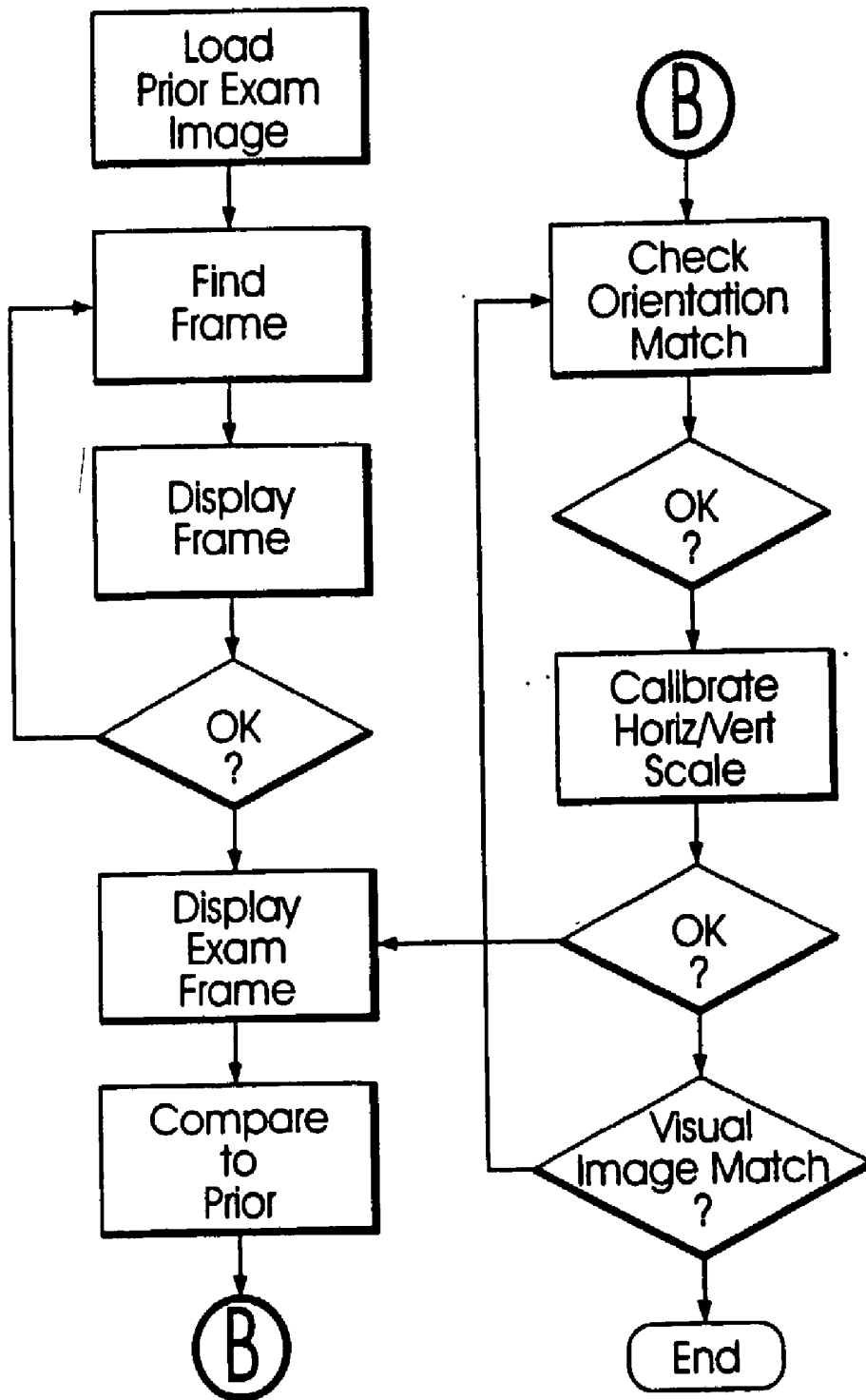


FIG. 7

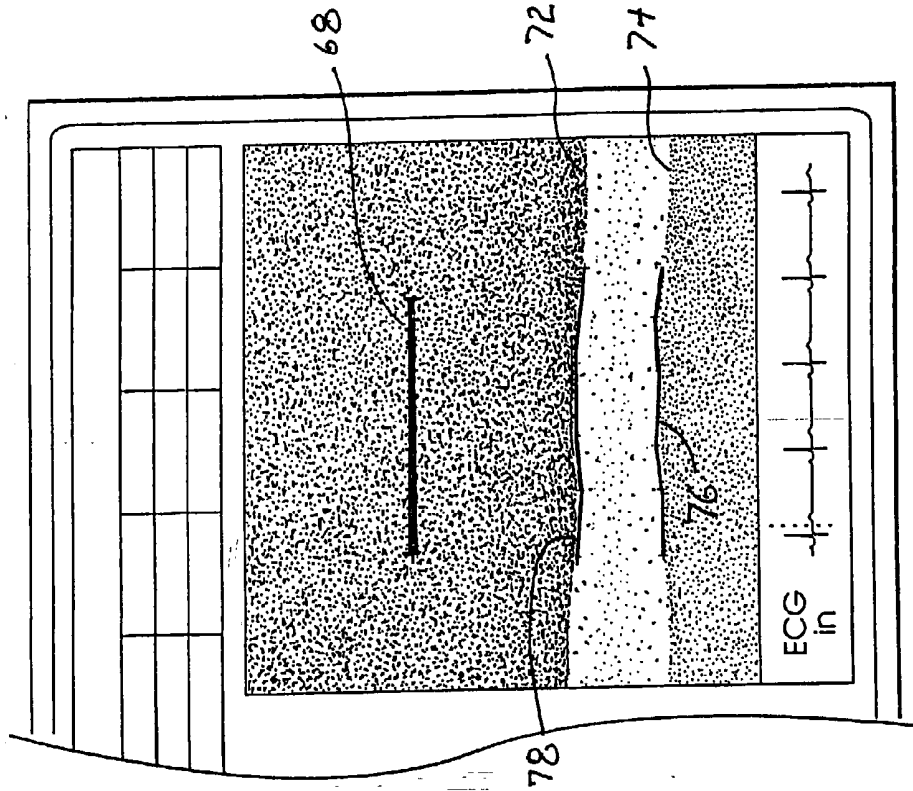


FIG. 9

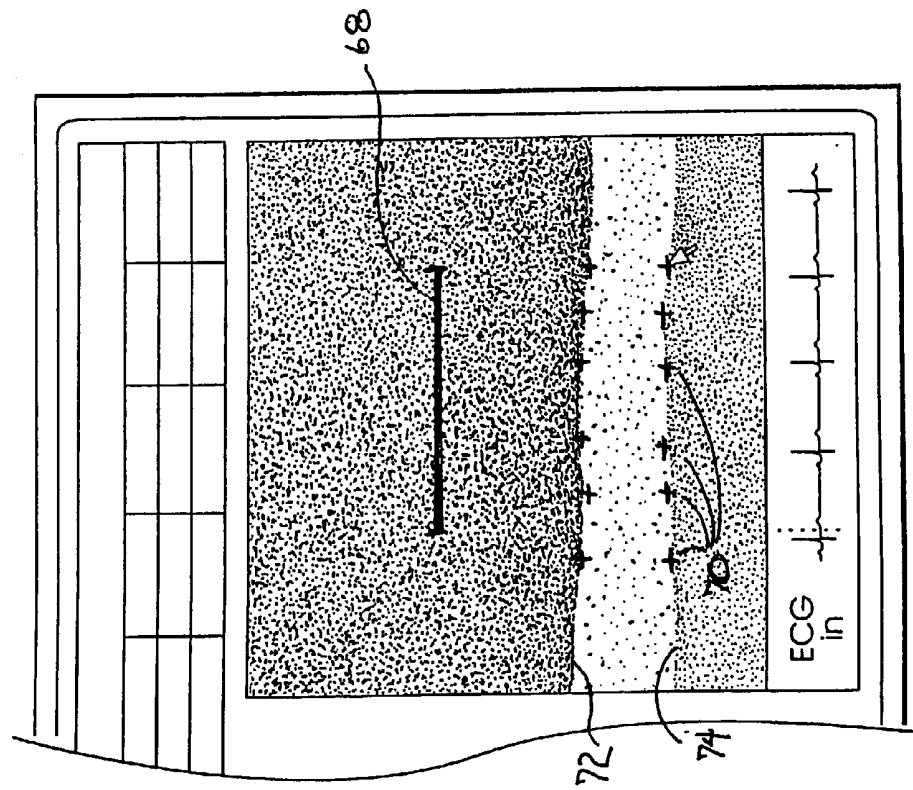


FIG. 8

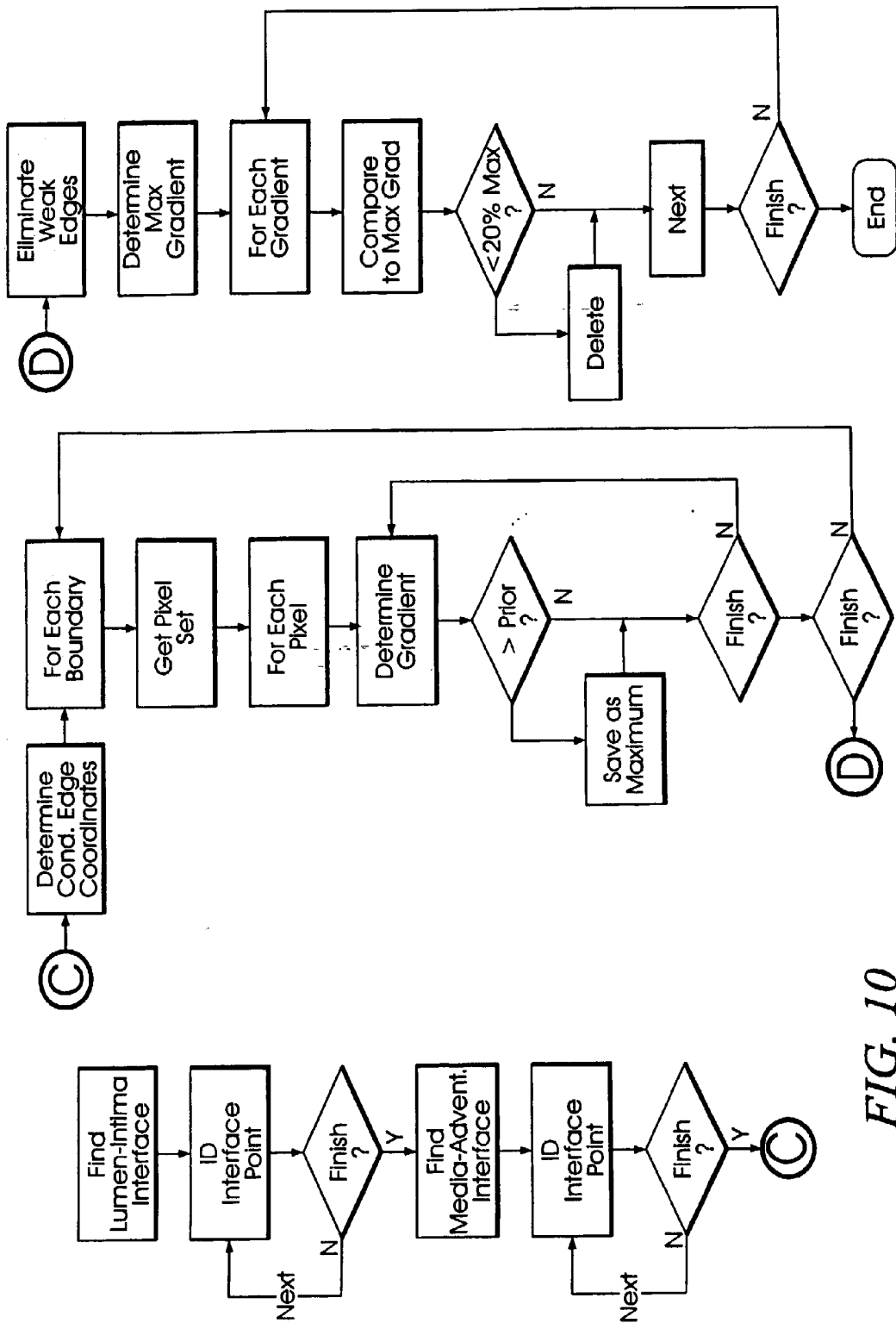


FIG. 10

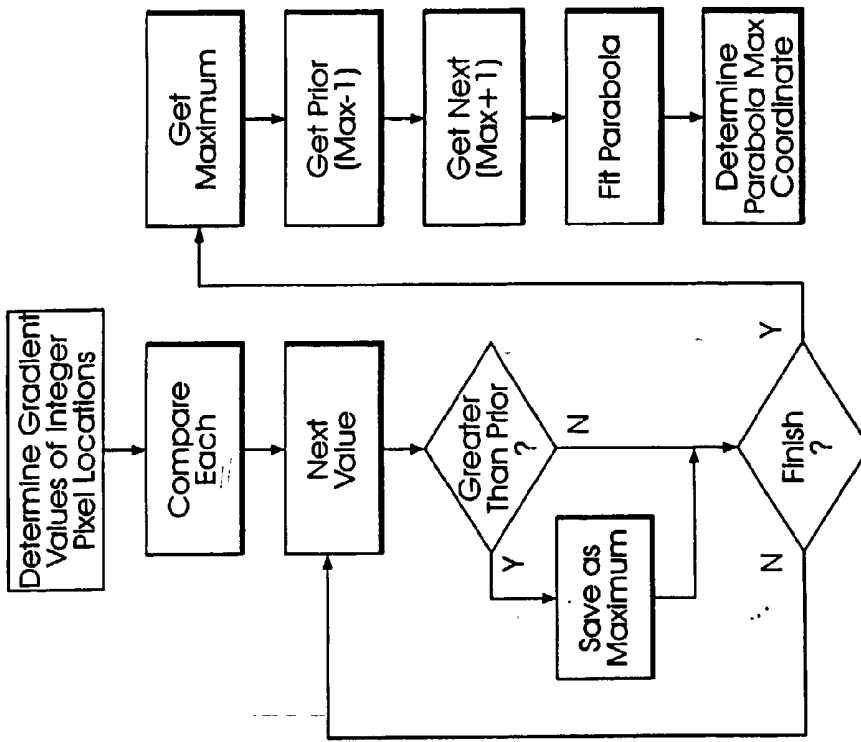


FIG. 11B

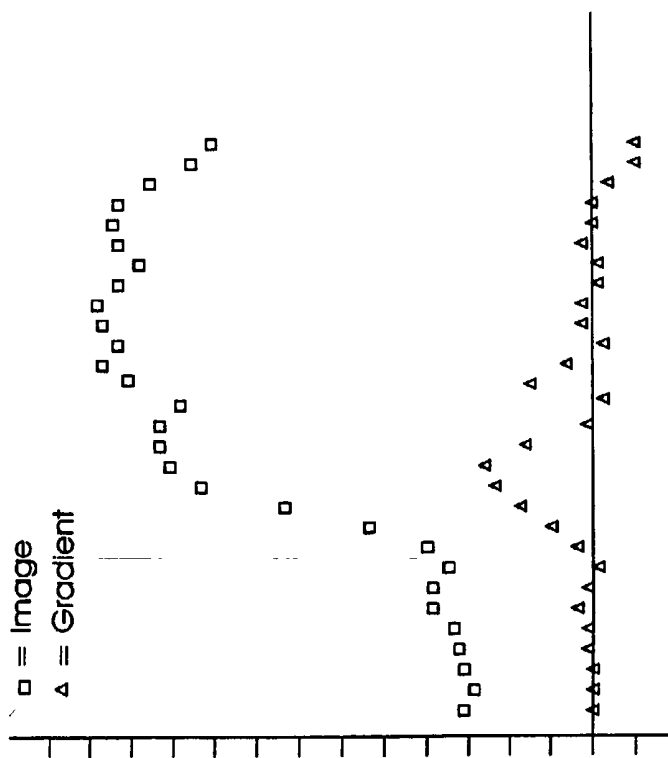


FIG. 11A

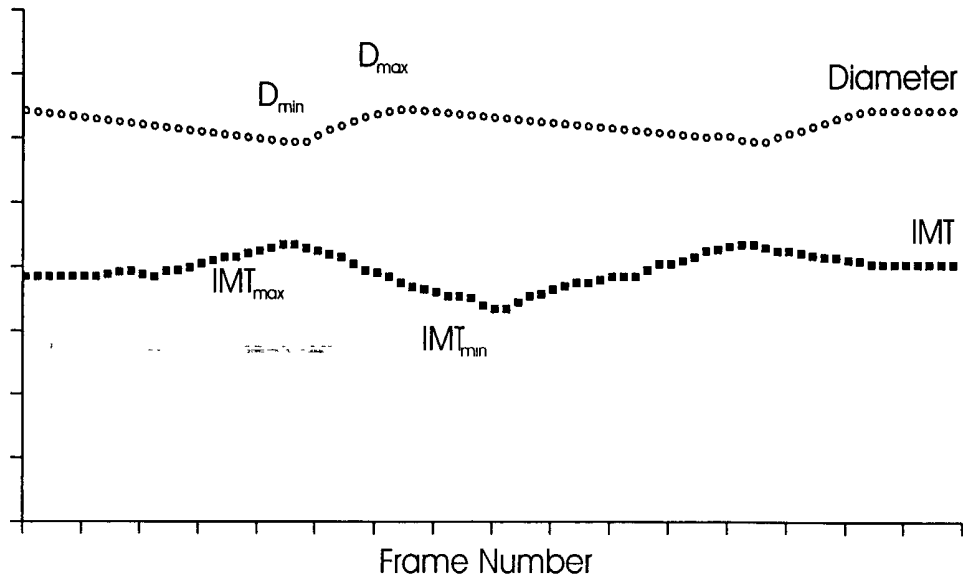


FIG. 12

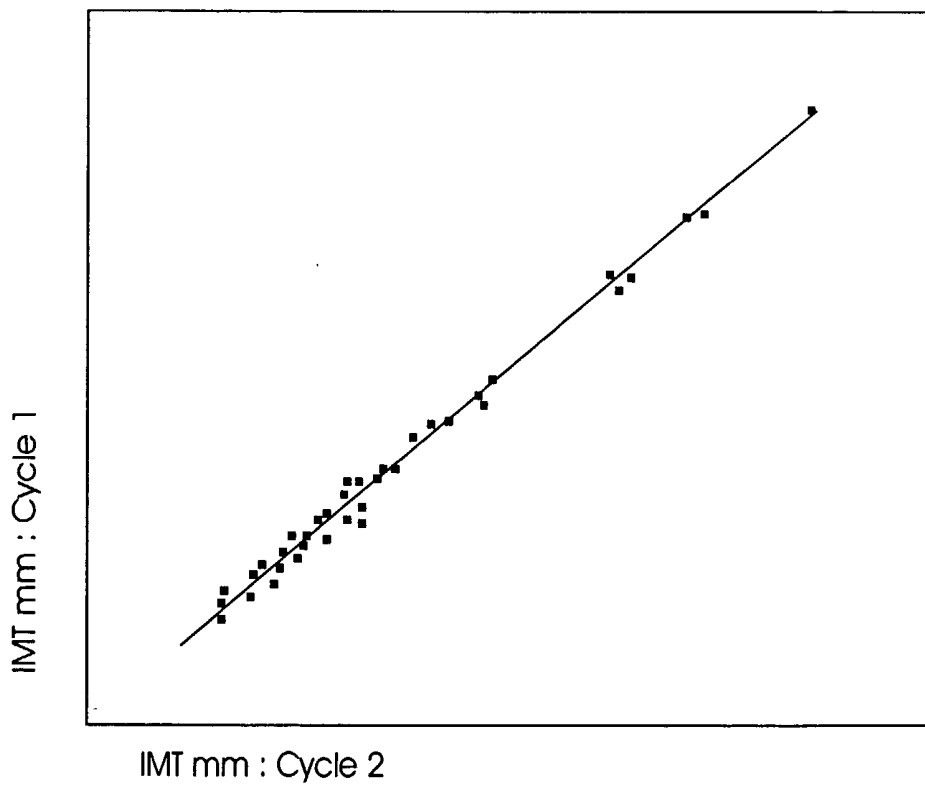
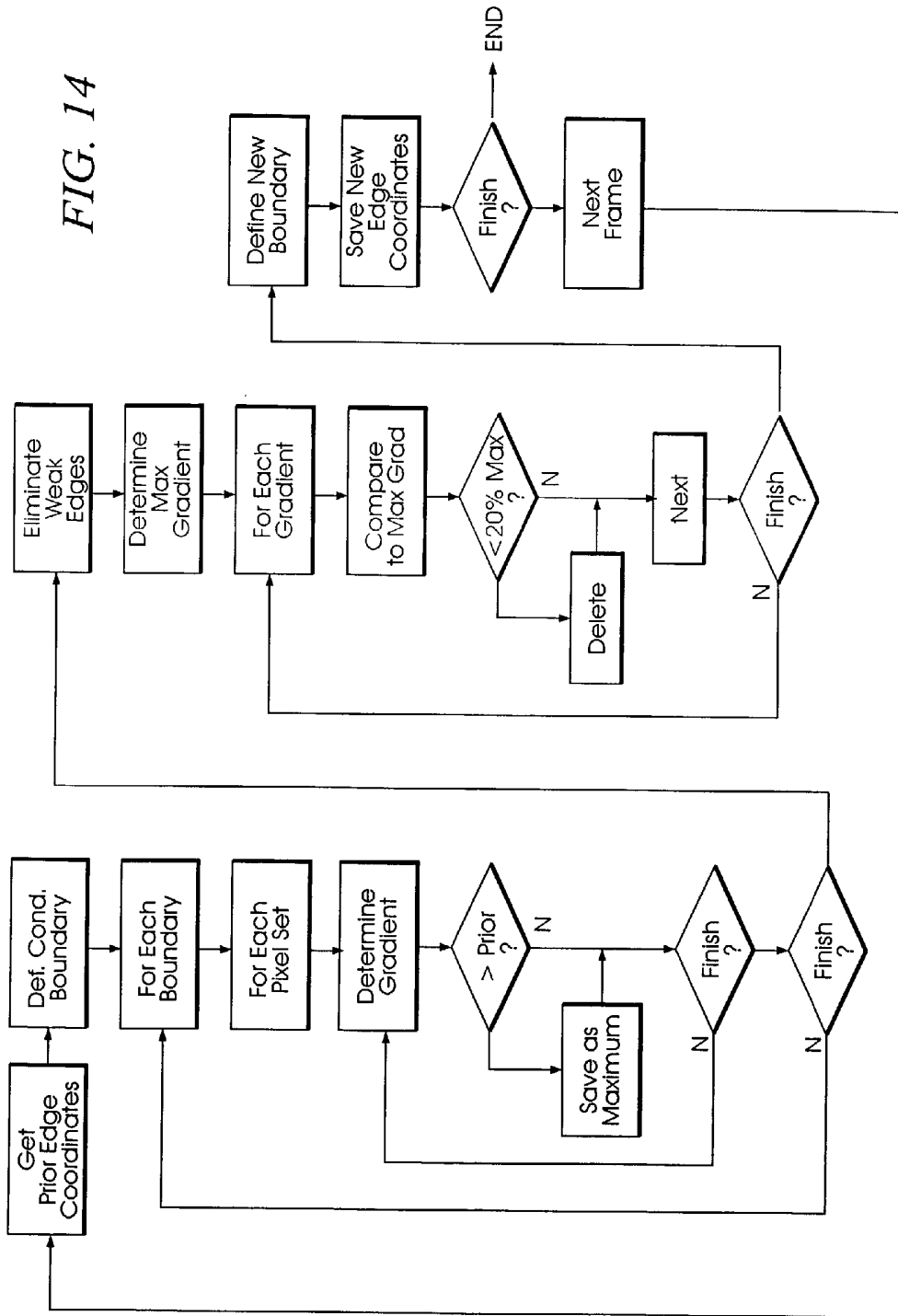


FIG. 13

FIG. 14



**SPLIT-SCREEN DISPLAY SYSTEM AND
STANDARDIZED METHODS FOR ULTRASOUND
IMAGE ACQUISITION AND MULTI-FRAME DATA
PROCESSING**

**CROSS REFERENCE TO RELATED
APPLICATIONS**

[0001] The present application is related to and takes priority from U.S. provisional patent application Serial No. 60/279,229, filed Mar. 27, 2001, entitled **MOTORIZED ROTATOR DEVICE FOR ULTRASOUND PROBE**, and is further related to co-pending U.S. patent applications entitled **SYSTEM AND METHOD FOR IMPROVING ULTRASOUND IMAGE REPLICATION FOR REPEATABLE MEASUREMENTS OF VASCULAR STRUCTURES**, **SPLIT-SCREEN DISPLAY SYSTEM AND STANDARDIZED METHODS FOR ULTRASOUND IMAGE ACQUISITION AND PROCESSING FOR IMPROVED MEASUREMENTS OF VASCULAR STRUCTURES**, and **MOTORIZED ULTRASOUND TRANSDUCER FOR REPEATABLE MEASUREMENTS OF VASCULAR STRUCTURES**, all filed on instant date herewith, all commonly owned by the assignee of the present invention, the entire contents of all of which are expressly incorporated herein by reference.

FIELD OF THE INVENTION

[0002] The present invention is directed to the field of ultrasonographic vascular visualization and vascular structure measurements and, more particularly, to standardized, reliable and reproducible ultrasonographic vascular imaging and structural measurements including intima-media thickness and vessel diameter determinations to yield anatomical and physiologic measurements.

BACKGROUND OF THE INVENTION

[0003] Cardiovascular disease remains the leading cause of morbidity and mortality in industrialized nations. An increase in arterial wall stiffness and thickness is the common pathological pathway for the factors that lead to initiation and progression of the vascular changes associated with cardiovascular disease. Functional disturbances of the vascular wall may occur early in the arterosclerotic process, even before the anatomical changes of intima-media thickening become perceptible. Therefore, study of dynamic and anatomic arterial wall properties of large arteries, such as the carotid and femoral arteries has become commonplace. Since the mechanical and structural properties of the arterial wall may change before the occurrence of clinical symptoms of cardiovascular disease, the non-invasive measurements of arterial wall properties has become common in the study of atherosclerosis and as an extremely important method for identifying individuals at risk for cardiovascular events. Therefore, standardized, improved and easily deployed methods for evaluating arterial wall structures and characteristics has important implications leading to earlier and more effective strategies for screening, prevention and treatment of atherosclerosis and cardiovascular disease.

[0004] Direct measurement of the arterosclerotic burden and its rate of progression can be determined by quantitative imaging of vascular structures. The only standardized imaging methodology currently available to determine coronary

and cerebrovascular atherosclerosis is angiography. However, this imaging technique is limited to luminal dimensions and only inferences about the extent of arterial wall involvement can be made. Further, since angiographic procedures are invasive, they cannot be performed in asymptomatic persons. Additionally, angiographic measurement of atherosclerosis is a relatively high variability procedure. As such, coronary angiography has no applicability in the screening for and in the prevention of atherosclerosis and cardiovascular disease. Other than B-mode ultrasonography, there is no reliable non-invasive technique available to directly measure atherosclerosis or its progression.

[0005] Accordingly, high resolution B-mode ultrasonography can be used to non-invasively and quantitatively image the atherosclerotic process in peripheral vessels reflective of coronary artery and cerebrovascular atherosclerosis. Measurement of carotid arterial wall stiffness and intima-media thickness (IMT) have been shown to reflect early subclinical atherosclerosis. Large epidemiologic and case-control studies have demonstrated an association between carotid arterial wall stiffness and IMT, measured by B-mode carotid ultrasonography, and cardiovascular, cerebrovascular and atherosclerosis risk factors in both men and women. The association between coronary and carotid atherosclerosis depends in part on exposure of both arterial beds to the same risk factors. Studies have demonstrated a strong relationship between carotid arterial wall stiffness and IMT and angiographic presence, extent, and progression of coronary artery disease in both men and women. Arterial wall thickness demonstrates as good or better correlation with coronary artery disease than does traditional lipid and non-lipid risk factors. Most importantly, carotid arterial wall stiffness and thickness predict clinical cardiovascular and cerebrovascular events in men and women.

[0006] Since the lumen-intima and media-adventitia echoes in carotid ultrasound images were first identified and histologically verified as an accurate measure of intima-media thickness of the arterial wall, B-mode ultrasonography has been used for non-invasive quantitative measurement of intima-media thickness (IMT) as a direct measurement of atherosclerosis. The methodology used to measure IMT has relied on human visual judgment in order to manually identify echo coordinates indicating the lumen-intima and media-adventitia boundaries. The accuracy, reproducibility and precision of IMT measurements, determined by manual identification methods, are limited by human variability in the operation of coordinate designation devices and by the resolution of the displayed ultrasound image.

[0007] Recently, certain automated IMT measurement techniques have become available which improve the accuracy and precision of such measurements. However, even though absolute IMT measurements are improved by automated techniques, measurement of changes in arterial IMT and diameter over time, which indicates progression or regression of atherosclerosis, must also be accurate, and repeatable in both time and space. Carotid images, acquired in different examinations, must be precisely replicated since very small changes in the ultrasound view of the artery can cause large changes in the IMT or diameter measurements.

[0008] While standardized positioning procedures assist in minimizing changes, a patient's position on the examination

table can rarely be reproduced exactly in different examinations. Thus, identical images cannot be obtained under these conditions. Attempts to superimpose images from different examinations using color coding or image subtraction have not been successful for both technical and procedural reasons since small differences in image acquisition, which are always present, as discussed above, are exaggerated in the superimposed color coded or subtracted images, making interpretation difficult at best. These image differences are driven by the limited reproducibility image acquisition techniques currently available.

[0009] The need for a standardized methodology by which carotid artery images are acquired and IMT and arterial dimensions are measured in an accurate and reproducible form will become apparent when it is recognized that ultrasonography has distinct advantages over any of the other techniques currently available for evaluating carotid arterial vascular structures such as the intima-media thickness and diameter, and physiologic structures such as arterial wall stiffness as cumulative measures of generalized atherosclerosis. In particular, high resolution B-mode ultrasonography is readily available to practitioners. It is inexpensive, easy to perform, poses no risk, and can be repeated as frequently as desired. Most importantly, it can be used in healthy, asymptomatic individuals to determine the extent and progression of atherosclerosis. Accurate determination of carotid arterial anatomy (IMT and diameter measurements) and physiology (stiffness and compliance) is possible, with the entire process of carotid artery image acquisition and measurement taking approximately 30 minutes.

[0010] Utilizing this technique, measurement of the rate of atherosclerosis progression can be envisioned as part of a yearly physical examination. Although readily employed as the most common measure of atherosclerosis progression in clinical trials and human studies, further standardization of this methodology for application in screening, prevention and treatment of atherosclerosis and cardiovascular and cerebrovascular disease is still required.

[0011] This needs to be accomplished at the earliest time possible, such that practitioners can more accurately and cost-effectively screen individuals at risk for a cardiovascular or cerebrovascular event and to design therapies on an individual basis in the prevention and treatment of atherosclerotic disease.

SUMMARY OF THE INVENTION

[0012] In one aspect of the invention, a standardized method for obtaining an accurate and reproducible vascular characteristic measurement comprises performance of an ultrasonographic examination of vascular structures and capturing ultrasonographic images under a standardized procedure.

[0013] In one aspect of the standardized imaging acquisition procedure, a current image in real-time is visually compared with a recalled image acquired in a previous examination on a split-screen display system. The previous ultrasound image is recalled and displayed on a first-half portion of a split-screen display during performance of a current examination. An ultrasonographic image of the same vascular structures is displayed in real-time on a second-half portion of the split-screen display. During the course of the present ultrasound examination, the image in real-time is

visually compared to the recalled image and the ultrasonographic transducer orientation is adjusted until the current image substantially matches the recalled image.

[0014] A system for obtaining accurate and reproducible images and measurements of vascular structures comprises a high resolution ultrasound system operating in B-mode and includes a high frequency transducer, the transducer developing ultrasound images in a plane oriented in accord with a major axis of the transducer. An image recording system receives and records images captured by the ultrasound system and a computer processor, including an image digitizer, is coupled to the ultrasound system and the image recording system. The computer processor displays digitized ultrasound images on a split-screen display.

[0015] An image acquisition/analysis application, hosted on the computer processor, receives a stored digitized ultrasound image taken during a previous examination and allocates the retrieved image to a first screen location of the split-screen display. The image acquisition/analysis application then allocates a digitized ultrasound image taken during a present ultrasound examination to a second screen location of the split-screen display. An operator compares the two views so as to match the real-time ultrasound image, taken during a present ultrasound examination procedure, to the retrieved stored ultrasound image taken during a previous examination procedure.

[0016] In a further aspect of the invention, a standardized method for accurately replicating ultrasound images of vascular structure, taken at spaced-apart examination intervals, so as to develop a set of substantially congruent sequential images of vascular structure, comprises the steps of orienting an individual such that a the neck is exposed after the head is counter-rotated about 45 degrees with a head positioning apparatus, and positioning an ultrasound transducer so as to capture a transverse image view through a neck section that contains the carotid artery and jugular vein. The transverse view is displayed on a split-screen display and transducer position and angulation are manipulated until the jugular vein and carotid artery are displayed in a substantially vertical stack orientation with the jugular vein above the carotid artery, the stack orientation defining an approximate vertical axis through a center of the jugular vein and a center of the carotid artery. The transducer is then rotated around the central image line (the vertical axis) through approximately 90 degrees, so as to capture a longitudinal image view along a length of the carotid artery while maintaining the jugular vein stacked above the carotid artery.

[0017] Particular features of the standardized method of the invention include displaying the longitudinal image view of the jugular vein stacked above the carotid artery, in real-time, on a first half portion of a split-screen display and retrieving a stored longitudinal image view of the jugular vein stacked above the carotid artery taken during a previous ultrasound examination and displaying the previous longitudinal image on a second half portion of the split-screen display. Transducer position is further manipulated so as to bring the real-time longitudinal view into congruence with the retrieved longitudinal view by visual comparison of the first and second half portions of the split-screen display.

[0018] Advantageously, each longitudinal view of the carotid artery includes an image of a portion of a carotid

artery bulb structure, each longitudinal view further including an image of at least a length of a far wall portion of the carotid artery distal to the carotid bulb. Further, a set of display characteristic parameters, such as ultrasound settings, associated with acquisition of the previous longitudinal image from a previous ultrasound examination are retrieved and the set of display characteristic parameters are displayed for the repeat ultrasound examination and replicated in real-time. In other words, instrumentation acquisition parameters are replicated from one examination to another within the same individual.

[0019] In a particular aspect, the invention comprises a standardized method for acquiring reproducible ultrasound images and performing standardized and reproducible intima-media thickness (IMT) and vascular structure measurements, the measurements taken in substantially the same location of the carotid artery in each of a plurality of time-spaced-apart examinations. A first ultrasound image of a longitudinal section of a carotid artery is obtained, the image including a carotid artery bulb portion as a reference location. An intima-media thickness (IMT) measurement is performed on an arterial wall portion of the carotid artery distal to the carotid bulb and the first ultrasound image is stored as a prior ultrasound examination image in a memory store. Arterial lumen dimensions are also measured at the same arterial wall segment used for the IMT measurement.

[0020] Subsequently, a second ultrasound image of a longitudinal section of a carotid artery is obtained, with the image including the carotid bulb portion as a reference location. The second image is displayed in one portion of a split-screen display and the first image, retrieved from the memory store, is displayed in another portion of the split-screen display. The ultrasound transducer is manipulated until the second image visually matches the first image.

[0021] A computer processing system, in accordance with the invention, develops vascular characteristic measurements from ultrasound images and comprises a video recorder, the recorder storing vascular ultrasound images taken during the course of an ultrasound examination procedure. A mass data storage memory unit stores vascular ultrasound images taken during the course of a previous ultrasound examination procedure, a digitizing and image processing system, and a computer processing unit coupled to the video recorder, mass data storage memory unit, and digitizing system. A split-screen display system, coupled to the computer processing unit, displays a digitized vascular ultrasound image retrieved from the memory storage unit on one side of the split-screen display and displays a digitized vascular ultrasound image taken from the video recorder on the other side of the split-screen display.

[0022] Advantageously, the computer processing system includes an analysis engine hosted on the computer processing unit, the analysis engine including means for establishing an approximate boundary location of a first interface region of a portion of an arterial wall structure, means for establishing an approximate boundary location of a second interface region of said portion of the arterial wall structure; and means for establishing an actual interface edge, for the first and second interface regions, within a plane region centered about the corresponding approximate boundary location. A vascular characteristic calculation engine returns vascular characteristic measurement calculations, such as

IMT and lumen dimensions, made with respect to the actual interface edges of the first and second interface regions.

[0023] An automated method for obtaining vascular properties measurements from multiple, sequential ultrasound image frames comprises the steps of obtaining ultrasound images from a standardized region of a common carotid artery, where the images characterized as a multiplicity of digitized sequential image frames taken over at least two cardiac cycles. The multiplicity of sequential frames are stored and a first digitized frame is displayed on a computer display. An approximate boundary location of a lumen-intima interface of a standardized segment of an arterial wall structure is established in a quasi-manual fashion, as is an approximate boundary location of a media adventitia interface of the standardized segment of the arterial wall structure. The method includes automatically identifying an actual lumen-intima interface edge in a region proximate the approximate boundary location of the lumen-intima interface and automatically identifying an actual media adventitia interface edge in a region proximate the approximate boundary location of the media adventitia interface. A representation of the identified lumen-intima and media adventitia interfaces is stored in pixel form or in a mathematical representation.

[0024] A subsequent digitized sequential frame is displayed and the approximate boundary locations of the lumen-intima and media adventitia interfaces of the subsequent frame are established on the basis of the automatically identified lumen-intima and media adventitia interface edges of the first frame. The actual interface edge storing, subsequent digitized sequential frame displaying and automatically establishing approximate boundary locations steps are repeated for each sequential frame of the multiplicity.

[0025] In one aspect of the invention, for each frame, a plurality of pixel locations corresponding to the lumen-intima and media adventitia interfaces are automatically marked. The plurality of pixel locations is fixed, for each one of the lumen-intima and media adventitia interface edges, with a curve, the curve mathematically describing the lumen-intima and media adventitia interfaces edges. Pairs of pixel points corresponding to vertically opposed pixel locations are defined, each pixel pair defining a separation distance between the lumen-intima interface and the media-adventitia interface. The marking, fitting and defining steps are performed on a far wall portion of a standardized segment of a common carotid artery, and the marking, fitting and defining steps are performed on a near wall portion of said standardized segment of a common carotid artery. Further, the marking, fitting and defining steps are repeated for each sequential frame of the multiplicity.

[0026] An intima-media thickness measurement is plotted for each frame in sequence, as is an arterial diameter measurement for each frame in sequence. A minimum arterial diameter and a maximum arterial diameter are determined from the plotted arterial diameter measurements. Intima-media thickness is determined at a frame time corresponding to both the minimum and maximum arterial diameters. An intima-media thickness measurement is plotted for each frame in the sequence. An arterial diameter measurement is made for each frame in the sequence. A minimum arterial diameter is determined from the plotted arterial diameter measurements and a maximum arterial

diameter is identified from the plotted arterial diameter measurements. Intima-media thickness is determined at a frame time corresponding to both the minimum and maximum arterial diameters.

DESCRIPTION OF THE DRAWINGS

[0027] These and other features, aspects and advantages of the present invention will be more fully understood when considered with respect to the following specification, appended claims, and accompanying drawings wherein:

[0028] FIG. 1 is a simplified illustration of a superficial dissection of the right side of the neck, showing the right common, internal and external carotid arteries and jugular vein in their approximate anatomical positions;

[0029] FIG. 2 is a simplified illustration of jugular vein/carotid artery stacking, taken along the transverse plane AA of FIG. 1;

[0030] FIG. 3A is a simplified illustration of a longitudinal view of the right jugular vein stacked above the right common carotid artery and bulb, following transducer rotation in accordance with practice of the present invention;

[0031] FIG. 3B is a simplified illustration of carotid arterial wall detail, including the intima-media complex;

[0032] FIG. 4 is a simplified block-level flow diagram of an ultrasonographic examination procedure in accordance with practice of the present invention;

[0033] FIG. 5 is a semi-schematic, block-level diagram of an ultrasonographic carotid artery image acquisition and measurement system for standardized image acquisition for standardized arterial dimension measurements, in accordance with the present invention;

[0034] FIG. 6 is a simplified representation of a screen shot depicting one embodiment of a split-screen display system implemented for vascular image acquisition and vascular measurements such as arterial dimensions and intima-media thickness (IMT) in accordance with the present invention;

[0035] FIG. 7 is a simplified flow diagram of a carotid artery view comparison procedure in accordance with the invention;

[0036] FIG. 8 is a simplified representational screen shot of one side of the split screen display of FIG. 6, depicting a zoomed-in view of a selected ultrasound frame, illustrating boundary marker placement;

[0037] FIG. 9 is a simplified representational screen shot depicting the selected frame of FIG. 8, illustrating a best fit curve generated through the boundary markers;

[0038] FIG. 10 is a flow diagram of one embodiment of an intima-media thickness (IMT) determination methodology;

[0039] FIG. 11A is a graphical representation of image intensity and computed intensity gradient, along one sample edge;

[0040] FIG. 11B is a simplified flow chart of one embodiment of a maximum gradient calculation procedure;

[0041] FIG. 12 is a graphical representation of continuous measurement of arterial diameter and IMT over successive cardiac cycles;

[0042] FIG. 13 is a graphical representation of a comparison of IMT measured at minimum diameter during successive cardiac cycles; and

[0043] FIG. 14 is a simplified flow chart of one embodiment of a multi-frame measurement acquisition and analysis procedure.

DESCRIPTION OF THE INVENTION

[0044] B-mode ultrasound has gained popularity as a non-invasive method for direct visualization of superficial vessels. With B-mode ultrasound, arterial stiffness and intima-media thickness (IMT) can be directly measured since image acquisition of the arterial wall thickness and vessel diameter can be obtained simultaneously in a dynamic fashion throughout the cardiac cycle. The present invention relates generally to a standardized method of carotid artery B-mode ultrasound image acquisition with a computerized split screen system, and carotid arterial diameter and intima-media thickness (IMT) measurements from B-mode ultrasound images which utilizes computerized edge tracking. Multi-frame image processing automatically measures arterial diameter and IMT in multiple sequential frames spanning several cardiac cycles. Further, in accordance with the invention, a computerized methodology assists operators to accurately replicate images obtained from a particular individual over several spaced-apart examinations. The methodology utilizes a split-screen display in which the arterial ultrasound image from an earlier examination is displayed on one half of the screen while a real-time "live" ultrasound image from a current examination is displayed next to the earlier image on the other half of the screen. By viewing both images, whether simultaneously or alternately, while manually adjusting the ultrasound transducer, an operator is able to bring into view the real-time image that best matches a selected image from the earlier ultrasound examination. Utilizing this methodology, measurement of vascular dimensions such as carotid arterial IMT and diameter, the coefficient of variation is substantially reduced to values approximating from about 1.0% to about 1.25%.

[0045] In a summarized form, the present invention concerns video ultrasound signals, obtained either directly from a commercially available ultrasound imaging system, or from a VCR playback of prerecorded video signals, which are directed through an image digitization system configured on a personal computer (PC). Ultrasound images are continuously digitized in real-time and displayed on one side of a computer graphical split-screen display. During an initial ultrasound examination, an operator views the computer display with the ultrasound transducer positioned so as to visualize the carotid artery. When the computer display shows a carotid artery image that is considered suitable for IMT or arterial diameter measurements, the operator right-clicks a mouse which interrupts the digitization process and stores the digital image appearing on the screen at that time as a "selected" digital image.

[0046] During a second or subsequent examination, the stored image from the first examination is displayed on one half of a computer's graphical split-screen display, while the above-described procedure is utilized in order to capture the real-time arterial image controlled by an operator's movement of the transducer, on the other half of the screen. When

the image from the present examination best matches the image from the previous examination, the operator "clicks" a mouse, as previously described, to identify and store the new present examination image.

[0047] Following image capture of a single frame, arterial diameter or IMT is measured as a two frame average. If a sequence of sequential frames are captured, the dynamic mechanical properties of the arterial wall are dynamically measured over several cardiac cycles with a computerized edge tracking, multi-frame processing methodology that measures arterial diameter and IMT in multiple sequential frames. Carotid arterial diameter and IMT dimensions, measured in B-mode ultrasonograms, by computerized edge tracking, multi-frame processing are highly reproducible, particularly when it is understood that arterial wall properties are measured in substantially the same place, over the same distance, on an individual-by-individual basis, even over multiple examinations ranging over a period of months to years. The accuracy and reproducibility of the standardized image acquisition methodology, as well as the computerized edge tracking, multi-frame processing methodology function, in combination, to define a non-invasive, inexpensive, simple to use system which is well within the capabilities of practitioners or other caregivers.

[0048] FIG. 1 illustrates a superficial dissection of the right side of a human neck, so as to show the position of the right common carotid artery 10 and the jugular vein 12. As is well understood by those having skill in the art of anatomy, the jugular vein is external to, runs alongside, and overlays, for at least a portion of its length, the carotid artery. For purposes of illustration and ease of explanation, the jugular vein is depicted in the exemplary embodiment of FIG. 1 as having been resected in order to expose a portion of the carotid artery beneath it.

[0049] The carotid artery 10 traverses from the torso to the neck in the region of the fore portion of the clavicle, proximate the thyroid gland. The common carotid portion ascends the neck until it bifurcates into an external carotid branch 14 and internal carotid branch 16, at a location that is near (but could be somewhat above or below) the corner of the mandible. The region where the common carotid 10 branches into the external carotid 14 and internal carotid 16 includes a region termed the carotid bulb 18. The carotid bulb 18 is that portion of the common carotid 10 where the arterial diameter increases in order to form a "bulb" shape, just before the common carotid artery branches into the internal and external carotid arteries.

[0050] Recognizing the carotid artery bulb 18 is a particularly important feature of the present invention, since it is a distinctive feature which can be visualized during image acquisition by B-mode ultrasonography, and which provides a convenient structural reference point for an operator's location, longitudinally, along the common carotid artery. In a manner that will be described in greater detail below, visualization of the carotid bulb 18 allows an operator to define a physical location along the arterial wall in relation to the carotid bulb at which arterial wall characteristic measurements may be performed on a repeatable basis. Performing a repeated measurement at a standardized location (i.e., approximately 0.5 centimeters below the inception of the carotid bulb, in a direction opposite blood flow).

[0051] In the course of an arterial visualization process, in accordance with the present invention, high resolution

B-mode ultrasound images of the right or left common carotid artery are obtained utilizing a 7.5 to 10 MHz linear array sonogram transducer coupled to a conventional ultrasound apparatus. Patients are placed in a supine position, with the head rotated approximately 45° to the left or right, using a 45° head pillow; in an aspect approximated by the illustration of FIG. 1 (the embodiment FIG. 1 depicts the head rotated approximately 45° to the left).

[0052] The transducer is initially positioned to develop a transverse view of the region of the neck including the jugular vein and carotid artery. Such a transverse view might be developed along a transverse plane indicated by the line AA in FIG. 1. The jugular vein 24 and carotid artery 26 are located in the transverse view with the jugular vein stacked above the carotid artery, as illustrated in the exemplary cross-sectional anatomical diagram of FIG. 2, taken along plane AA of FIG. 1. With regard to FIG. 2, it should be understood that an ultrasound transducer operating in the 7.5-10 MHz range captures an image from the point of contact (i.e., at the transducer/epidermis interface) to about 3 to 5 centimeters (typically from about 4.0 to about 4.5 centimeters) within the neck tissue. Thus, the image seen on an operator's split-screen display (represented by FIG. 2) would suitably comprise the epidermal layer 20 at the top of the screen and a region of soft tissue 22 below the epidermal layer 20 and intermediate the epidermal layer and the jugular vein 24. The lumen of the jugular vein necessarily appears circular and is substantially darker in color than the surrounding tissue, making it quite easy to visualize sonographically. Just beneath the jugular vein 24, the common carotid artery 26 also appears as an object having a dark, circular lumen 25 surrounded by lighter or brighter colored soft tissue 27, termed the intima-media complex. If the patient's head was positioned correctly, at the appropriate 45° deflection, the transverse sonographic view should show the jugular vein 24 positioned directly above the common carotid artery 26.

[0053] In the exemplary embodiment of FIG. 2, the jugular vein is depicted as outlined by a lighter colored wall complex. Those familiar with ultrasound visualizations of the jugular vein will recognize that the jugular vein appears as dark colored structure with little circumferential delineation. The jugular vein, 24 is outlined in FIG. 2 only for purposes of clarity of identification and ease of explanation, and not as any indication of structure.

[0054] Care is taken to position the transducer in a way that displays the jugular vein and carotid artery images stacked, jugular vein above the carotid artery to bring the central image line of the jugular vein 24 and carotid artery 26 into substantial vertical alignment in the sonographic transverse image plane. Bringing the jugular vein into a stacked alignment with the carotid artery is a particularly important feature of the methodology of the present invention, since it allows for establishment of a standardized, repeatable reference position from which all subsequent transducer manipulations are made. It is also important to bring the stacked jugular/carotid structure to the center of the transverse sonographic image, for reasons that will be explained in greater detail below.

[0055] Once the jugular and carotid are located in the transverse view, with the jugular vein stacked above the carotid artery, the transducer is rotated 90° around the

central image line of the transverse image of the stacked jugular vein/carotid artery, in order to obtain a longitudinal image, while maintaining the two vessels in the stacked position. An illustration of a longitudinal view, through a longitudinal section of the right common carotid artery and jugular vein, following transducer rotation, in accordance with practice of principles of the invention, is shown in **FIG. 3A**.

[0056] Capturing an ultrasound image in this fashion, allows for a very consistent and standardized method for image acquisition of the longitudinal view of the carotid artery, such that tangential thickness perturbations are substantially minimized, if not eliminated. Obtaining a longitudinal section (view) of a cylindrical vessel farther and farther off-axis, results in substantially increasing wall thicknesses and an apparent decrease in arterial diameter, with increasing displacement outwardly from the vessel's central axis. In order to obtain repeatable images for repeatable measurements of the arterial wall thickness and arterial diameter from a cylindrical vessel, the longitudinal view must be necessarily obtained, if not along the axis, then at least at a known and reproducible position displaced from the axis. Initially stacking the jugular vein and carotid artery in the initial transverse view, and aligning the stacked structure in the center of the image field, allows for repeatable longitudinal imaging, at the axis, with a simple 90° rotation of the transducer around the central image line.

[0057] As will be described in greater detail below, variability in transducer rotation techniques are substantially reduced, if not eliminated, by creating a fixed reference position for rotation, at the time of transverse view acquisition. This can be assisted when the ultrasound transducer is configured in a holder that rotates in a cylindrical housing. The housing of the ultrasound probe rotator device rests on the neck of the subject and acts as an anchor or fixed reference point. The holder is coupled for precise rotation by a stepper motor, for example. The operator need only manually manipulate the transducer in order to develop the appropriate transverse view, and then activate the motorized holder, which rotates the transducer through 90°, with respect to a fixed reference position. Thus, so long as the operator is able to reproduce the stacked, transverse image of the jugular vein/carotid artery complex, the motorized rotator device/transducer automatically and repeatedly develops the appropriate longitudinal image along a reproducible plane of the cylindrical vessel.

[0058] In the exemplary illustration of **FIG. 3A**, and with regard to the arterial wall detail illustration of **FIG. 3B**, it will be understood that the longitudinal image is positioned along the carotid so as to contain anatomical landmarks for reproducing probe angulation, including stacking of the jugular vein **24** above the carotid artery **26** and visualization of the carotid bulb **18**. An experienced operator will recognize the shape of the carotid bulb **18** and anatomy of the jugular vein and carotid artery and so position the image so as to expose an approximately 2 centimeter long region of the common carotid artery below the inception of the bulb along with juxtaposition of the jugular vein. Visualization of the region where the common carotid artery divides into the interior and exterior carotid arteries, termed carotid artery bifurcation **29**, is also helpful in reproducing image position.

[0059] In this regard, and with particular attention to **FIG. 3B**, it will be understood that all arteries are generally

formed of three distinct layers, an intima, media and adventitia, but the proportion and structure of each varies with the size, type and function of the particular artery. The innermost layer, the intima **30**, suitably comprises a layer of endothelial cells which is characteristically thin in a young normal vessel, but which becomes thickened with age and other causes of atherosclerosis (e.g., genetics, lipid dyscrasias, smoking, hypertension, and other risk factors for vascular disease, atherosclerosis and cardiovascular disease). The middle layer, the media **32**, contains smooth muscle cells. The media also suitably contains layers of elastic lamellae that alternate with layers of smooth muscle cells in elastic arteries, but with smooth muscle cells dominating in muscular arteries. The outer layer, the adventitia **34**, typically contains loose connective tissue, nerves, small blood vessels and smooth muscle cells, particularly in large veins. A histological feature of larger arteries is the presence of longitudinally arranged smooth muscle cells in this layer.

[0060] In terms of ultrasound images, the individual layers comprising an exemplary common carotid artery wall are not independently visualized. Indeed, ultrasound reflections are generated at the interface between the blood lumen **36** and the intima layer **30**, as well as the interface between the media **32** and adventitia **34**. Thus, ultrasound images allow visualization of a region corresponding to the intima-media combination; thus, the term intima-media thickness (IMT), also referred to as the intima-media complex.

[0061] IMT measurements are made from the deep (or far) wall of the artery farthest from the skin starting in a region approximately 0.5 centimeters distal to the carotid bulb along a 1 centimeter length, using a standardized, computer generated "lock-out" ruler, away from the carotid bulb along the common carotid artery, and reflect a thickness of the intima-media complex defined by the near ultrasound reflection from the lumen-intima interface, and the far ultrasound reflection from the media-adventitia interface. Images are acquired by performing an ultrasound scanning procedure with an ultrasound system depicted in the exemplary embodiment of **FIG. 5**. In **FIG. 5**, a conventional, high resolution ultrasound apparatus **40** is coupled to a high frequency transducer **42** which is typically configured as a small part, vascular transducer. The transducer is conventionally a 7.5 to 10 MHz linear array transducer, and is coupled to any one of a series of commercially available ultrasound imaging systems. Exemplary systems include the ATL Ultramark IV, manufactured by ATL of Bothell, Wash., Toshiba SSH 140A ultrasound system, or other generally similar apparatus operating in B-mode. Images obtained by the ultrasound system **40** and transducer **42** are recorded on a video cassette recorder (VCR) **44** so as to be available for subsequent review. Additionally, an electrocardiograph (ECG) **46** is coupled to the system so as to provide an ECG signal from the patient that is recorded simultaneously with image acquisition and a trace of the ECG signal is superimposed on the ultrasound image. In conventional fashion, the ECG **46** receives a signal from conventionally placed electrodes **48** affixed to the patient's body in conventional fashion. Additionally, a time coder **47**, counting in 100 ms intervals is coupled to the ultrasound system so as to provide a time code (time stamp or time reference) on each ultrasound frame. Each image frame is given an identifiable code used to locate individual frames or sets of frames for efficient retrieval.

[0062] Images acquired by the ultrasound system 40 are directed to a computer processing system 48 for acquired image display and analysis. Computer processing system 48 is contemplated as comprising a personal computer system (PC) including a graphic split-screen display monitor 50 and further including a non-volatile mass storage unit 52 such as a hard disk drive, JAZ drive, or a readable/writable CD ROM. It should be noted that there are very little processing constraints placed on the computer processing system 48. Indeed, a personal computer system utilizing an Intel 386-type processor and operating at speeds less than 100 MHz is certainly sufficient for practice of principles of the present invention. Those having skill in the art will understand that a more capable and faster computer system will be able to practice aspects of the invention with a greater degree of efficiency and speed, but raw processing power is not strictly required for the system to function quite adequately.

[0063] Prior to image analysis, a video image of the carotid artery is converted into a 512×480 pixel digital array, with 256 grey levels per picture element. Digitization is accomplished with an Epix PIXCI-SV4 or similar digitizing and image processing board 54 coupled to the computer processing system 48 through an internal bus, for example. The digitizing/image processing board 54 allows digitization of all images received either directly from the ultrasound system 40, or through playback of the VCR 44. Thus, images shown on the computer system's graphic split-screen display 50 are all digitized into a 512×480 pixel format.

[0064] The video signals from ultrasound systems are formatted to match the standards established for each region. In North America, the standard is 30 frames per second with 480 visible lines per frame. Each line is digitized into 512 picture elements (pixels) so that the digitized image size is 512 by 480 pixels. The European standard in most areas is 50 frames per second with 512 visible lines per frame. In this case, the digitized image is 512 by 512 pixels. The number of lines per frame is fixed by the video standard but the number of digitized pixels per line can be more or less than 512. This number was selected to allow two images to be displayed side-by-side on a commonly used 1024 by 768 computer split-screen display. A higher resolution computer display could be used but the size of the displayed image becomes smaller and more difficult to see.

[0065] Notwithstanding the foregoing, the display format is also chosen because of certain peculiarities pertaining to certain video cassette recorders. For example, a Sony VO 9500 MD VCR contains a digital memory that allows the computer to digitize a full 480 line video frame with the VCR in still mode. However, VCRs without frame memory display only half-frame fields (240 lines) in still mode. Since accurate frame selection for IMT measurements requires the use of VCR still mode display, frame memory is a desirable feature in order to obtain full image resolution in the digitized image. Images are digitized to full frame resolution when the VCR is in normal play mode, but frame selection is a difficult process with the tape moving at normal playback speed.

[0066] Further, although the Sony VO 9500 MD VCR includes a digital frame memory, the digital data are not directly accessible to the computer processing system. In this particular example, the only VCR output is an analog signal, derived from the frame buffer and, as a result, a digitizing board is required in the computer system.

[0067] The process of digitizing the video ultrasound image, tracking the lumen-intima and media adventitia echoes, and computing IMT and arterial dimensions is accomplished with an application software program running on the computer processing system 48. Operation of this application software routine will now be described in connection with the exemplary screen shot depicting a split-screen implementation of an IMT measurement system of FIG. 6, in combination with a simplified flow diagram of a carotid artery longitudinal view comparison procedure of FIG. 7. It should be apparent that while the application software program is described more in connection with measurement data processing, those operational portions that support split-screen image display are particularly useful in connection with the image acquisition process described above.

[0068] Briefly, the application software routine implements a methodology that assists an operator to repeatedly acquire images in a standardized fashion and accurately replicate measurements on images that have been obtained over different, spaced-apart examinations. The methodology utilizes a split-screen display, in which an arterial ultrasound image from an earlier examination is displayed on one side 56, for example, of a split-screen display 50, while a current ultrasound image from the current examination is displayed on the other side 58 of the split-screen display. By viewing both images, while manually adjusting the ultrasound transducer, an operator is able to find the real-time image that best matches the earlier image.

[0069] Specifically, the earlier arterial image 56 is one of several image frames that were chosen for analysis during a previous examination. Each frame was chosen for the clarity of the image produced, and the quality of the IMT (i.e., well defined boundary echoes with a minimum of voids and discontinuities). These images were processed and IMT measurements and vascular dimensions taken therefrom, in a manner to be described in greater detail below, with all of the data pertaining to each frame stored in a file or set of files in non-volatile mass storage memory (52 of FIG. 5) or on a JAZ Drive or CD ROM identified to a particular patient. A menu bar 60 is disposed along the top of the split-screen display 50 and comprises a set of selectable tasks from which the application software routine is operable. Such tasks necessarily include "get file" so that an operator is able to select and extract previous images for a particular patient, by accessing their file data and uploading the information contained therein. As described above, images contained within the file are displayed on the left-hand side of a split-screen display 56. Additional menu items might include commands to "advance" which, when selected, might advance from one frame to another within the selected file, displaying each frame in the left-hand screen portion 56.

[0070] As presently contemplated, there are approximately 25-30 commands disposed within the menu area 60 which represent the most frequently used commands made to the program. Additional pull-down menus contain further commands less frequently used. Frequent commands include "Record Dir," which displays records in a selected database file, "Store New" which stores a selected record as a new record, and "Replace Rec" which replaces a stored database record with a current selected record. "Set Tracking" is used to select if arterial diameter or IMT is to be measured and to set other properties of the tracking display.

Other commands, such as "Show Pts", allow an operator to display previously selected manual tracking markers and "Fix Pts" allows an operator to adjust manual tracking markers, as will be described in greater detail below. Further, "Zoom/Unzoom" allows an operator to zoom an image by various multiplication factors and "Step Frame" allows the operator to step through a database record-by-record in order to apply corrections if necessary.

[0071] A "Digitize" command puts the frame grabber (digitizing and image processing board) into a continuous digitized/display mode. Mouse access (by right clicking, for example) terminates the sequence, in effect freezing the image. All newly digitized images are temporarily identified with a temporary file name, such as digit.dmp until the image is given a permanent name with the command "Name Image". An "Image Right" command displays the current image to be processed on the right side of the split-screen display 58, which is the screen portion where tracking and measurement functions are operative. An "Image Left" command is used to position a reference image on the left side 56 of the split-screen display 50. As an example, an image from a prior ultrasound examination is stored in an active folder and a matching image is located from a current ultrasound examination from a videotape or from a direct feed from an ultrasound transducer. The image from the prior examination is placed on the left side of the split-screen display while the "Digitize" command implements real-time images from the videotape or transducer on the right side of the screen for comparison. Further tracking, calibration and measurement commands will be discussed in more detail below, during that part of the software operation regime that pertains to image processing for IMT and arterial dimension measurements.

[0072] In accordance with the exemplary image acquisition procedural flow diagram of FIG. 4, and the exemplary measurement preparation procedural flow diagram of FIG. 7, prior ultrasound examination images are displayed on the left side 56 of the split-screen display 50 in order that an operator is able to evaluate positioning of the transducer so as to obtain a present image that corresponds to the previously stored image in as great a degree as possible. The particular shape, aspect and general appearance of the previous image serves as a visual reference to the operator in order to obtain as exact a replication as possible. During image acquisition, minute adjustments in transducer probe position and angulation are made until such time as the real-time present image 58 closely matches all of the parameters of the stored image 56. In this regard, for each individual and for each examination, the depth of field, gain, monitor intensity setting, and all other initial instrumentation settings used for a baseline examination, are recorded for each set of images contained in any one database and are maintained therein for all follow-up examinations. Although, a hard copy of each individual's baseline image might be used as a guide to match a repeat image to a baseline image, the split-screen methodology discussed in connection with FIGS. 4, 6 and 7 define a preferred direct visual aid methodology for reproducing probe angulation.

[0073] Image comparison and matching is also performed during a standardized measurement process, as depicted in FIG. 7. In particular, a set of images acquired in accordance with the standardized acquisition process described above during a prior examination is extracted from a "prior exami-

nation" database, and a suitable frame is displayed on one half of the split-screen display as a reference image. The displayed frame should correspond to a frame upon which IMT and/or vascular dimension measurements were made during the prior examination. Current examination ultrasound frames are displayed on the other half of the split-screen display and evaluated against the reference frame in order to find the best match. The visual reference structures used to acquire the images also function to support a more reproducible match between images obtained and measured during the prior examination and those being evaluated for measurement during the current examination. Image matching during the measurement as well as the acquisition procedures reduces measurement variability and substantially improves the repeatability of arterial dimension measurements, thereby allowing effective long-term trend analysis.

[0074] As a further aid to reducing measurement variability, an ECG recording is displayed along a bottom portion 62 of the split-screen display, as well as time code information displayed in a top corner, in a manner that allows image frames to be selected based on their occurrence within a particular cardiac cycle (i.e., such that the same phase of the cardiac cycle is examined for all IMT and vascular dimension measurements). By way of an additional example, arterial diameter measurements need to be made at the times of maximum and minimum internal pressure, such that elasticity values may be obtained from maximum and minimum internal diameter measurements. It is well understood by those having skill in the art that maximum and minimum internal pressures have a direct relationship to the occurrence of a measurement with regard to the timing of the P-wave and R-wave.

[0075] Further, and in accordance with the invention, the greatest degree of accuracy and reproducibility is obtained when IMT measurements are made during the minima of arterial excursions (lowest carotid arterial distending pressure) which occurs in the ECG tracing between the P-wave and the R-wave. Thus, for each ultrasound examination, matching longitudinal views of the common carotid artery are located and approximately 80 successive frames, representing a minimum of two cardiac cycles, are digitized. The number of frames chosen is not particularly relevant to practice of the invention, since with conventional computer systems, 80 or more frames can be acquired and stored on a high speed hard disk drive in real-time from a single VCR pass. All that is necessary in the context of the invention is that a number of image frames be taken over at least two cardiac cycles, such that at least two to three frames will occur at any given portion of the cardiac cycle. Thus, an operator is assured of obtaining at least one frame per cycle that is properly positioned in the minima between the occurrence of the P-wave and R-wave of the ECG trace. Once these images are acquired and stored, the operator is able to recall the stored frames and once again compare them to the reference image located on the left side 56 of the split-screen display 50.

[0076] Whether viewing a current image or a recalled image on one side of the screen 58, the operator must ensure that the active image matches the reference image as closely as possible, not only in aspect and positioning, but also in the quality of the intima-media region and the reflection of the boundary edges. Additionally, the operator must ensure

matching of all of the anatomical references, such as the jugular vein, carotid bulb, etc, and the ECG phase (the p-wave, for example). With regard to reflection boundary quality, the lumen-intima and media-adventitia ultrasound echoes are optimally visualized when the ultrasound scan is perpendicular to the vessel walls. The transducer probe is positioned to maximize the brightness of the intima-media complex echo and minimize gaps in the echo. When the ultrasound beam is approximately perpendicular to the vessel wall, the reflected signal from the intima-media complex is maximized and produces the brightest signal. Similarly, the intima-media complex echo has the fewest gaps when the ultrasound beam is perpendicular to the vessel wall. Accordingly, it will be understood that the initial patient placement, transducer probe manipulation so as to obtain a visualization of jugular/carotid stacking, in the transverse view, and probe rotation about the stacked central image line axis to obtain visualization of jugular/carotid stacking in the longitudinal view, all function in combination to provide a standardized methodology by which image quality and reproducibility are ensured, thereby enhancing valid image matching.

[0077] In order to refine image matching, both the right and left side images must be displayed on the split screen system in accordance with a corresponding scale. In other words, the application routine must know the spacing in millimeters represented by adjacent picture elements (pixels) in both the horizontal and vertical direction, for each image. A "calibration" command is selected from the menu box **60** and for each calibration, vertical and horizontal, two points are identified whose real separation in millimeters is known. The operator is requested to identify each of two reference points, by cursor selection (mouse click, or the like) and then enter the known separation of the reference points in millimeters. In this regard, many ultrasound systems employ some form of reference grid marks in the vertical and/or horizontal direction in five or ten millimeter intervals, and these are of great utility in performing the calibration procedure. However, although these reference grids are helpful, care must be taken to validate the reference intervals. Generally, the greatest accuracy is obtained by identifying and selecting reference marks which are separated as far as possible. The process is repeated for both horizontal and vertical calibration and "pixel spacing horizontal" and "pixel spacing vertical" are saved for each image. Pixel spacing values for one image are normalized to the values obtained for the other, such that both images are displayed with respect to a unitary system of pixel spacing.

[0078] Once the image of the present ultrasound examination is matched to the image of a previous ultrasound examination, a number of frames are acquired from the present ultrasound examination sonogram, as described above, and stored in non-volatile memory for further processing. All of the instrumentation settings are captured and stored, along with the image, in a particular database associated with that specific patient. Time stamping and time coding are used so that each image, or set of images, is associated to a particular examination date, such that long-term evaluations of the mechanical and structural properties of the arterial wall may be precisely undertaken. The recently acquired images are analyzed by the software application program, in accordance with the invention, in order to track the near and far wall media-adventitia or lumen-intima echoes in order to derive arterial diameter over

an approximately 1 centimeter length of the common carotid artery at a standardized location starting approximately 0.5 centimeters distal to the carotid artery bulb. Additionally, the far wall lumen-intima echo, tracked over the same segment, is used together with the far wall media-adventitia echo to determine IMT. Arterial diameter and IMT, for each frame, are taken as the respective average of approximately 70-100 individual measurements of diameter and IMT acquired along the 1 centimeter segment (assuming there are 70-100 matched pixel pairs per centimeter).

[0079] In general, when a single frame is analyzed by the system, an operator uses cursor control to identify several points along each echo boundary (lumen-intima echo and media-adventitia echo). A smooth curve generated through these identified points, serves as a guide to an edge detection process, where the system searches in the vicinity of the generated curve for the true boundary, using an intensity gradient detection method to be described in greater detail below.

[0080] When multi-frame detection is required, only the first frame of a multi-frame sequence is processed in the above-described fashion. The second and additional frames reuse the true detected edge coordinates from the first frame as an approximation to the boundary curve for the edge detection process of the next frame. The true boundary of the second frame is used as an approximation for the third frame edge detection process, with the sequence being repeated until all frames have been detected. Operator intervention is only required when there is a discontinuity between frames, such that the artery moves a relatively large distance between frames and causes the automated edge tracking methodology to fail. This effect is most frequently seen during the systolic expansion of the artery, in which case the operator redirects the tracking routine to the general vicinity of the changed boundaries.

[0081] Once appropriate boundary conditions are obtained, maximum and minimum arterial diameters, and the IMT at the point of maximum diameter and minimum diameter are determined over each cardiac cycle. Arterial dimensions (IMT and diameter) are averaged over two successive cardiac cycles and the arterial diameter and IMT values are used, together with blood pressure measurements, to calculate several standard arterial stiffness indices (elasticity and compliance measurements).

[0082] Further, IMT measurements are obtained at the point of minimum and maximum arterial diameter in order to compare the difference in IMT during minimum and maximum arterial excursion. This is roughly equivalent to end-diastole and peak systole, respectively. It has been empirically determined that the point of minimum arterial diameter occurs approximately in the interval region **101** between the P-wave and the R-wave, and more particularly, in the region just at the end of the P-wave, as depicted generally at **102** in **FIG. 12**. Similarly, maximum arterial diameter occurs at a point, indicated generally at **104**, in the interval **103** between the end of the R-wave and the peak of the T-wave. Given the image acquisition methodology of the present invention, there are approximately two (on average) video frames occurring in the interval from the beginning of the P-wave to the minimum diameter point, as well as the interval from the minimum diameter point to the beginning of the R-wave and from the maximum diameter point to the

peak of the T-wave. There are approximately six (on average) video frames occurring in the interval from the beginning of the R-wave to the maximum diameter point. Thus, it will be understood that capturing a suitable number of frames over two complete cardiac cycles will almost always give one frame occurring at the requisite points, i.e., minimum arterial diameter and maximum arterial diameter.

[0083] A particularly advantageous feature of the invention allows for increased measurement accuracy by averaging measurement results obtained from two frames of information. This feature evaluates measurement data from sequential frames occurring in the ECG trace intervals and thereby minimizes variability resulting from location along the trace. Two frame averaging, in a manner similar to that described above, utilizes the respective average of approximately 70-100 individual measurements of diameter and IMT acquired along the standard 1 centimeter length of each frame. Additionally, two frame averaging may be performed on two frames that occur at substantially the same time, with respect to the ECG trace, but during consecutive cardiac cycles. Frame averaging is thus useful in reducing inter-cycle variability as well as intra-cycle variability.

[0084] The lumen-intima and media-adventitia echoes are located in accordance with a three-step methodology that will now be described in connection with the exemplary screen shots of FIGS. 8 and 9 and the flow diagram of an IMT measurement methodology of FIG. 10. Initially, a selected frame is displayed on the operative (tracking) portion of the computer processing system's split-screen display (50 of FIG. 6) and a calibration procedure is performed, such that the image size is correlated to pixel data, as previously described. The image may be expanded in order to zoom-in on an appropriate region of the arterial far wall and the lumen-intima and media-adventitia echoes visually confirmed. An approximate echo boundary is identified and delineated for both the lumen-intima and media-adventitia boundaries by a series of cursor-placed boundary markers. The approximate boundary for each echo is used to guide an automated edge finding algorithm in order to locate an initial or "conditional first-pass" set of edges. A second set of approximate markers are derived from the first-pass edges by using the row coordinate of the first-pass edge row coordinates that correspond to each column of the initial markers. The sequence of fitting a smooth curve through the new markers and using this new approximate boundary as a guide for edges, is repeated. The second-pass computer-defined edges are then tested for "edge strength" and false or weak edges are eliminated. It should be noted that initial manual placement of boundary markers functions only to narrow the boundary search parameters for the system. Actual boundary definition and subsequent measurements performed with respect to the defined boundaries are performed automatically by the system. Accordingly, human measurement error is virtually eliminated.

[0085] In determining an approximate echo boundary, cursor boundary markers are placed at the leading edge of the echo at a few points, within a 1 centimeter horizontal range. In order to standardize the 1 centimeter range, a 1 centimeter scale 68 is superimposed over the image in order to define the region in which cursor points will be considered value, as illustrated in the exemplary embodiment of FIG. 8. The scale 68 is computer generated and functions as a "lock out" scale by defining a horizontal region within which

boundary markers may be placed for measurement. Only those markers disposed within the 1 centimeter horizontal range delineated by the "lock out" scale will be recognized by the system for further processing. Those markers outside the range of the scale will be ignored. Manual boundary markers, indicated generally at 70, are placed on both the lumen-intima and media-adventitia echo leading edges, 72 and 74 respectively, with the cursor boundary markers being a different color for each edge, in order to provide a visual aid to the operator during the approximation process. In the event a particular cursor marker is misplaced, an operator may right-click, for example, on the marker thereby deleting it and then left-clicking in order to place the marker in a more advantageous position. Following cursor placement at both interface edges, and with reference to the exemplary embodiment of FIG. 9, the operator accesses a "curve fit" command by which the system generates a smooth continuous curve, for both the lumen-intima 76 and media-adventitia 78 edges which conforms to and includes each of the cursor-placed boundary markers.

[0086] Next, the system searches for edges in a direction perpendicular to the approximate boundary defined by the smooth continuous curve fit to the corresponding set of boundary markers. At each point (defined by each pixel along the horizontal) of the approximate boundary, 13 pixels of the image are automatically examined that lie along a line perpendicular to the boundary. The system automatically selects half of the examined pixels from one side of the approximate boundary and half from the other, with the central pixel chosen as the one comprising the approximate boundary itself. Since the approximate boundary is selected to coincide visually with the leading edge of the echo, coordinates of the "true" boundary edges typically fall within three to four pixels of the approximate boundary.

[0087] The system-determined echo boundary is defined as that point within the 13 pixel sequence at which the rate of intensity change (or intensity gradient) of the pixels is at a maximum. Specifically, the rate of change of intensity, at a particular pixel in the sequence, is computed as the derivative of a second degree polynomial fit to the five pixels centered on the pixel in question. The process is iterative, and repeats for each of the pixels, beginning with the third and ending with the eleventh. An exemplary graph of image intensity values and computed gradient at one point of an exemplary lumen-intima echo is depicted in FIG. 11A.

[0088] The integer location in the image of the pixel with the largest gradient is initially taken as the echo boundary, but, as discussed in greater detail below, the maximum gradient of the pixel sequence can often occur between pixels. Further, edges determined to sub-pixel resolution are considerably more accurate than edges determined to an integer pixel resolution. For example, and with regard to sub-pixel edge detection resolution, two identical maximum gradient values might be obtained for two adjacent pixels. In this particular situation, the maximum gradient for the sequence might be selected as the point mid-way between the two pixels.

[0089] In order to determine a sub-pixel maximum gradient location, the nine gradient values, corresponding to integer pixels three through eleven, are determined in the manner as described above, and the resulting values are compared to determine the largest value. A parabola is fitted

to the three gradient values centered on the largest value and the coordinate of the parabola maximum is taken as defining the sub-pixel edge location.

[0090] The coordinates of edge points determined by the maximum gradient location procedure are labeled as conditional edge points and are converted to true edge points, or discarded, based on gradient value uniformity calculations. After conditional edges are determined for all points (each pixel along the 1 centimeter horizontal distance), the gradient value for each pixel along the conditional edge is compared with the maximum gradient value found for all the points along the conditional edges of that particular echo. Conditional edge points having gradient values less than 20% of the maximum value are considered "weak" edge points and are subsequently deleted, with the remaining edge points deemed acceptable. This procedure minimizes identification of spurious edge points due to image noise, voids, defects, or other perturbations in the arterial wall image. The 20% value is arbitrary, but was chosen because of certain image generation characteristics of particular ultrasound scanner apparatus. For a range of carotid images obtained with certain ultrasound systems, spurious edges often tend to be accepted when the deletion threshold is set at a value lower than about 20%, and valid low intensity edges tend to be rejected when the deletion threshold is set at a higher value. The 20% threshold value is considered suitable for use in connection with images generated from the majority of ultrasound apparatus in common use. Naturally, as ultrasound imaging technology improves, the rejection threshold may be further refined through simple empirical test procedures, in order to further improve the accuracy of edge detection.

[0091] After the edge tracking process has been applied to the lumen-intima and the media-adventitia echoes, the distance between all acceptable edge point pairs along the 1 centimeter distance are measured, averaged, and the mean separation between all the acceptable edge point pairs computed as IMT. The process is repeated for the media-adventitia edge points and, for each acceptable media-adventitia edge point, a line is drawn that is locally perpendicular to the media-adventitia edge points and which intersects the lumen-intima boundary. Gaps in the lumen-intima boundary, due to deleted edge points, are temporarily filled by linear interpolation from the pixel coordinates of the nearest acceptable edge points, in order to define acceptable edge point pairs.

[0092] Where the lumen-intima edge point closest to this line is an original acceptable edge point (i.e., not an interpolated edge point), it is paired with the media-adventitia edge point and the distance between the pixel edge points is calculated to the nearest pixel. Where the nearest lumen-intima edge point is an interpolated edge point, the media-adventitia edge point under consideration is assumed not to have a matching edge point and the media-adventitia edge point is discarded and the process is repeated for the next media-adventitia edge point until all edge point pairs are either used for IMT distance calculations or discarded.

[0093] Average IMT is computed as the mean of the calculated distance between all acceptable edge point pairs. By way of example, IMT for an average adult will fall in a range of approximately 0.65 to 0.9 millimeters, with the average being approximately 0.75 millimeters. On average,

acceptable matching edge points can be found for about 70% to about 80% of the potential edge point pairs of a standardized 1 centimeter portion of a typical arterial wall image.

[0094] With respect to arterial diameter measurements, it will be understood by those having skill in the art that the same methodology is applied to arterial near wall echoes as to the far wall echoes, with distances calculated between pixel pairs between the near and far wall lumen-intima boundaries, defined along a standardized 1 centimeter length.

[0095] The above-described standardized protocols and acquisition systems are particularly suitable for image acquisition and measurement of arterial wall thickness and vessel diameter, in a dynamic fashion, throughout the cardiac cycle, as the artery expands and contracts with each cardiac pulsation and relaxation, respectively. In order to process information relating to a complete cardiac cycle or cycles, the system suitably comprises a methodology for evaluating information taken from multiple, sequential image frames. For each ultrasound examination, performed in the manner described above, matching longitudinal views of the common carotid artery are located and captured, and approximately 80 successive image frames, representing a minimum of two cardiac cycles, are digitized. It will be understood by those having skill in the art, that 80 or more frames can be captured and stored on a contemporary mass data storage medium (such as a hard disk drive) in real-time from a single VCR pass, with a suitable computer system. It should be further understood that the number of frames acquired depends on the frame rate of the system. The actual number of frames, as well as the actual number of cardiac cycles over which the frames are taken is a matter of operator choice, and is not meant to be limiting in any manner. Once the necessary images are acquired, the above-described methodology is used to track the near and far wall media-adventitia echoes, in order to determine arterial diameter over the standardized approximately 1 cm length of the common carotid artery. The far wall lumen-intima echo, tracked over the same segment, is used together with the far wall media-adventitia echo in order to determine IMT. IMT and arterial diameter, for each frame, are defined as the respective average of approximately 70 to 100 individual measurements of IMT in diameter acquired along the standardized 1 cm segment.

[0096] In performing the analysis, the first frame, of a sequence of approximately 80 successive frames, is analyzed in accordance with the methodology described above, with the operator utilizing a mouse, or other pointing device, to identify echo edge point locations along each boundary in order to guide an automated edge detection algorithm. As described above, an automated smooth curve is generated through these points which functions as a guide to the automated edge detection process. The system then searches in the vicinity of this initial curve for the true boundary using the intensity gradient detection method described in connection with FIGS. 10, 11a and 11b. As depicted in the exemplary flow diagram of FIG. 14, the multi-frame processing methodology functions internally in a manner similar to the single frame processing technique; boundary conditions are defined automatically (using the set of prior frame determined edge coordinates) and for each boundary, pixel pair sets are generated. For each pair set, a maximum

gradient is determined, sets defining weak edges are eliminated and refined boundary edge coordinates are generated for that frame.

[0097] Only the first frame of an 80 frame sequence is processed in this particular manner. Processing of the second frame, and subsequent frames, utilizes the automatically detected edge coordinates from the first frame, or immediately preceding frame, as the approximate initial boundary for the subsequent frame's automated edge detection methodology. The true echo edge boundary is automatically determined and the sequence is repeated, for subsequent frames, utilizing the prior frame's detected edge coordinates as the approximate initial boundary for the instant frame's edge detection process. As each frame is processed, IMT and arterial diameter data is acquired for that frame and stored with respect to each frame.

[0098] Operator intervention is required only when corresponding arterial structure is displaced a relatively large distance between frames, thereby causing the edge tracking methodology to fail. This affect is most frequently observed during systolic expansion of the artery, when arterial motion is fairly rapid. When this occurs, the operator manually redirects the tracking system to the general vicinity of the changed boundaries, in substantially the same manner as described above, i.e., by marking the boundary edges, commanding the system to generate a smooth curve through the markers and automatically identifying the echo edges. Although operator intervention is supported, it is generally only required for about one or two frames per cardiac cycle.

[0099] In summary, when frame-to-frame movement of the artery is small, the tracking methodology described above is used to track sequential frames automatically, by using detected edges from one frame as a reference to search for echo boundaries in the next frame. Initial tracking is carried out by identifying a few guidance points along the boundary, fitting a smooth curve to the guidance points and using the resulting smooth curve to guide edge tracking using the maximum gradient method described. For multi-frame processing, the guidance points for the following frame are selected from the detected edge points of the current frame. Since the column coordinate of each guidance point is constant, the "next frame" guidance point is defined as a row coordinate of the current frame detected edges at the guidance point column coordinate. However, when frame-to-frame movement of the artery is large, such as commonly occurs during systole, tracking may fail at some portions of the boundary. An adaptive tracking correction methodology corrects these difficulties in a manner described further below.

[0100] Application of the automated multi-frame image processing methodology described in connection with FIG. 14, to all of the acquired frames, generates a sequence of arterial diameter and IMT measurements, over two complete cardiac cycles, as depicted in the exemplary graphical data plot of FIG. 12. As shown in the exemplary embodiment of the figure, vessel diameter expands and contracts depending on the cardiac cycle phase. Minimum vessel diameter is identified as D_{\min} while maximum vessel diameter is identified as D_{\max} . Likewise, measured IMT varies with cardiac cycle phase and, therefore, vessel diameter. In the figure, IMT_{\max} and IMT_{\min} correspond to maximum and minimum measured IMT, respectively.

[0101] In order to remove discontinuities and ensure data integrity, an adaptive tracking filter is applied, as described further below, to the sequence of measurements and the maximum and minimum arterial diameters and IMT, at the point of maximum and minimum diameter, are determined over each cardiac cycle. The arterial dimensions (IMT and diameter) are averaged over two successive cardiac cycles and are subsequently used to calculate several standard arterial stiffness indices. From the graphical data plot of FIG. 12, it will be recognized that IMT measurement results depend on arterial diameter, with IMT exhibiting an inverse correlation to diameter.

[0102] Improved selection of "next frame" guidance points is performed by a more effective adaptive tracking filter methodology in accordance with the invention. Adaptive tracking correction is applied following the edge detection step, as described above. A minimum least square error curve is fit to all of the "good" detected edges. Where the arterial segment is substantially linear, a linear fit is used, but a parabolic curve is also implemented where the arterial segment exhibits substantial or obvious curvature. The choice between a linear or parabolic curve is determined automatically by well known curve fitting algorithms. However, this choice can be made by an operator, after inspection of the arterial segment.

[0103] For each guidance point column coordinate, the position (row coordinate) of the edge point is evaluated against the position (row coordinate) of the least square curve for that column. If the vertical deviation of the point from the least square curve exceeds a predetermined value, the row coordinate of the least square curve is used for the next frame guidance point. The predetermined value is set at a reasonable value at the choice of the operator, but typically has a value of 1 pixel.

[0104] This procedure minimizes the likelihood that a tracking error that occurs at the column coordinate of a guidance point will be propagated to subsequent frames. Further, the absolute value of all guidance point deviations from the least square curve, provides a measure of how well the detected edges followed the guidance points. Necessarily, a large deviation suggests that the guidance points were poorly defined for that frame. This might well be the case where tracking is fairly accurate on one portion of an arterial segment, but tracking on another portion "loses" the boundary due to contrast or brightness changes. When this average deviation reaches or exceeds a predetermined threshold value (user definable), tracking for that frame can be repeated with each guidance point's row coordinate changed to coincide with the row coordinate of the least square curve for the corresponding column.

[0105] It will now be understood that both IMT and diameter depend upon where during a cardiac cycle the measurement is taken. Multi-frame processing supports a simple and effective methodology whereby maximum and minimum IMT can be identified, without having to rely on a visual match between ECG traces. Further, multi-frame processing allows for efficient calculation of arterial stiffness indices such as Peterson's elastic modulus, Young's modulus, arterial distensibility, compliance and the beta stiffness index. Further, adaptively correcting certain measurements over multiple frames (particularly IMT over several frames centered at the minimum arterial diameter) reduces single

frame measurement variability substantially, compared with a single frame measurement (measuring IMT from a single frame corresponding to minimum arterial diameter). Nevertheless, it has been determined that IMT, for example, measured at the minimum arterial diameter position during one cardiac cycle correlates strongly to IMT measured at the minimum arterial diameter position during the subsequent cardiac cycle. An exemplary graph of IMT values obtained during cycle 1, plotted as a function of IMT values obtained during cycle 2, is shown in FIG. 13. A best fit curve through experimental data points (taken from a single individual) shows a characteristic 1:1 relationship.

[0106] These particular features are important, since in arterial imaging, reproducibility of end point data determines the smallest change that is able to be measured. Reproducibility necessarily influences the length of a data collection cycle in order to achieve a specified significance level and power to detect change. Accordingly, the above-described methodology significantly reduces the variability of IMT measurements since IMT measurements are performed at the same point in the cardiac cycle, thereby reducing the extrema of IMT. IMT measurements are preferably taken at end-diastole, when IMT is thickest. Further, the point of maximum and minimum IMT is chosen based on arterial diameter, rather than reliance upon an ECG trace, since there is a phasic discordance between maximum and minimum arterial diameters and the ECG signals.

[0107] It should also be understood that the advantages of the above described methodology apply equally to vessel diametric measurements. Vessel mechanical properties, such as stiffness and the like, are derived directly from diameter measurements which should be taken in a consistent, repeatable manner in accordance with a standardized procedure.

[0108] It will be understood, therefore, that high resolution B-mode ultrasonography can be used to measure the dynamic mechanical properties of the arterial wall over several cardiac cycles easily and rapidly with an automatic edge tracking, multi-frame processing methodology, that measures arterial diameter and IMT in multi-sequential frames. A major advantage in measuring arterial wall stiffness from B-mode images is that the automated edge tracking, multi-frame processing methodology can be readily applied, without requiring extra views or changes in ultrasound parameters to image analysis of previously acquired images, including those recorded on videotape without simultaneous ECG recording. Data concerning arterial wall stiffening can be extracted from existing epidemiological data, with this technology, with minimal additional investment. The technology is readily deployed and requires no modification of existing ultrasound imaging equipment for arterial diameter and IMT measurements. Automated edge tracking, multi-frame processing of B-mode ultrasound images is a highly reproducible, readily available methodology for evaluating arterial diameter, IMT, and vessel wall properties.

[0109] The foregoing has been an exemplary description of a standardized protocol and system for the acquisition and processing of radio frequency ultrasound images of human vascular structure. An antero-lateral longitudinal view of the far wall of the right or left common carotid artery is obtained with the head disposed approximately 45° in the contralateral direction. The lumen-intima and media-adventitia echoes are optimally visualized when the scan lines are perpendicular to the arterial wall. The transducer is positioned in order to maximize the brightness of the far wall

IMT echo and to minimize gaps in the echo. When the ultrasound beam is approximately perpendicular to the wall, the reflected signal from far wall IMT echo is maximized and produces the brightest signal. Similarly, the far wall IMT echo has the fewest gaps when the ultrasound beam is perpendicular to the vessel wall.

[0110] In order to so position the ultrasound beam and ensure repeatability of image acquisition and measurement on an examination-by-examination basis, an operator first acquires a reference image defined by a stacked structure comprising the jugular vein and carotid artery, with the jugular vein and carotid artery disposed in a specific relationship such that the ultrasound beam will be perpendicular to the vessel wall, as the transducer is rotated 90°.

[0111] The proximal portion of the carotid bulb is included in the image for reference purposes to allow for image matching and standardized measurements on an examination-by-examination basis. All images are captured using the lowest power and signal gain consistent with the visualization of the arterial wall echoes.

[0112] One end diastolic frame is selected from a 5-10 second recorded sequence, using maximum IMT continuity and maximum echo brightness as a selection criteria. Further, the selected frame is chosen from a number of suitable frames based upon a matching procedure carried out on a split-screen display, with present examination images shown on one half and prior examination images shown on the other. The frame with the best visual match and containing suitable continuity and brightness criteria is selected.

[0113] Average IMT is computed over a 1 centimeter length of the common carotid artery far wall beginning approximately 0.5 centimeters distal to the transition between the common carotid and bulb regions. This transition region is identifiable in most cases by a relatively abrupt change in the angle of the far wall at the beginning of the bulb. The longitudinal position of the analyzed segment is carefully matched to the longitudinal position of analyzed segments of that particular patient's prior examination, by again performing a split-screen display comparison of the present and prior images.

[0114] The foregoing description of systems, standardized protocols, algorithms and standardized procedures for improving and standardizing ultrasound image acquisition for replication for repeatable vascular characteristic measurements have been set forth in connection with certain exemplary embodiments which are intended only as illustrations of the present invention and are not intended to represent the only forms in which the present invention may be constructed and/or utilized. It will be evident to one having skill in the art, that major simplifications, modifications and enhancements may be made to the exemplary embodiments and the same or equivalent functionality may be accommodated without departing from the spirit and scope of the invention. For example, image resolution may be increased with improved ultrasound transducers. However, for applications in which IMT and vascular dimensions serve as a clinical trial end point, absolute accuracy of the IMT and vascular dimension measurements is not as important as the error in detecting IMT and vascular dimension change. The systems and standardized methods described above are certainly adequate for developing IMT measurements with an absolute error substantially less than 5%. Accordingly, the present invention is intended to encompass the full scope and spirit of any structure, protocol or method that falls within the coverage of the appended claims.

What is claimed is:

1. An automated method for obtaining vascular properties measurements from multiple, sequential ultrasound image frames, the method comprising:

obtaining ultrasound images from a standardized region of a common carotid artery, the images characterized as a multiplicity of digitized sequential image frames taken over at least two cardiac cycles;

storing the multiplicity of sequential frames;

displaying a first digitized frame on a computer display;

establishing an approximate boundary location of a first interface region of a portion of an arterial wall structure;

establishing an approximate boundary location of a second interface region of the portion of the arterial wall structure;

automatically identifying a first actual interface edge in a region proximate the boundary location of the first interface region;

automatically identifying a second actual interface edge in a region proximate the boundary location of the second interface region;

storing the first and second actual interface edges;

displaying a subsequent digitized sequential frame on the display; and

automatically establishing approximate boundary locations of the first and second interface regions of the subsequent frame on the basis of the automatically identified first and second actual interface edges of the first frame.

2. The method according to claim 1, wherein the actual interface edge storing, subsequent digitized sequential frame displaying and automatically establishing approximate boundary locations steps are repeated for each sequential frame of the multiplicity.

3. The method according to claim 2, wherein the first interface region is a lumen-intima interface region and wherein the second interface region is a media-adventitia interface region.

4. The method according to claim 3, wherein the first and second actual interface edges define a brightness transition corresponding to the lumen-intima interface and the media-adventitia interface.

5. The method according to claim 4, further comprising:

for each frame, automatically marking a plurality of pixel locations corresponding to the first and second actual interface edges;

fitting the plurality of pixel locations, for each one of the first and second actual interface edges, with a curve, the curve mathematically describing the first and second actual interface edges; and

defining pairs of pixel points corresponding to vertically opposed pixel locations, each pixel pair defining a separation distance between the lumen-intima interface and the media-adventitia interface.

6. The method according to claim 5, wherein the marking, fitting and defining steps are performed on a far wall portion of a standardized segment of a common carotid artery, and

wherein the marking, fitting and defining steps are repeated for each sequential frame of the multiplicity.

7. The method according to claim 6, wherein the pixel point pairs are used to determine an intima-media thickness measurement for each frame.

8. The method according to claim 7, wherein an intima-media thickness measurement is determined for each sequential frame of the multiplicity, an average intima-media thickness measurement derived from adaptive tracking of the multiplicity of intima-media thickness measurements.

9. The method according to claim 5, wherein the marking, fitting and defining steps are performed on a far wall portion of a standardized segment of a common carotid artery, and wherein the marking, fitting and defining steps are performed on a near wall portion of said standardized segment of a common carotid artery, and wherein the marking, fitting and defining steps are repeated for each sequential frame of the multiplicity.

10. The method according to claim 9, wherein the pixel point pairs, for each frame, are used to determine an intima-media thickness measurement and an arterial diameter measurement.

11. The method according to claim 10, wherein an intima-media thickness and an arterial diameter measurement is determined for each sequential frame of the multiplicity, an average intima-media thickness and an average arterial diameter measurement derived from adaptive tracking of the multiplicity of intima-media thickness and arterial diameter measurements.

12. The method according to claim 11, wherein the multiplicity of stored sequential frames is approximately eighty frames.

13. An automated method for obtaining vascular properties measurements from multiple, sequential ultrasound image frames, the method comprising:

obtaining ultrasound images from a standardized region of a common carotid artery, the images characterized as a multiplicity of digitized sequential image frames taken over at least two cardiac cycles;

storing the multiplicity of sequential frames;

displaying a first digitized frame on a computer display;

establishing an approximate boundary location of a lumen-intima interface of a standardized segment of an arterial wall structure;

establishing an approximate boundary location of a media adventitia interface of the standardized segment of the arterial wall structure;

automatically identifying an actual lumen-intima interface edge in a region proximate the approximate boundary location of the lumen-intima interface;

automatically identifying an actual media adventitia interface edge in a region proximate the approximate boundary location of the media adventitia interface;

storing a representation of the identified lumen-intima and media adventitia interfaces;

displaying a subsequent digitized sequential frame on the display; and

automatically establishing approximate boundary locations of the lumen-intima and media adventitia interfaces of the subsequent frame on the basis of the automatically identified lumen-intima and media adventitia interface edges of the first frame.

14. The method according to claim 13, wherein the actual interface edge storing, subsequent digitized sequential frame displaying and automatically establishing approximate boundary locations steps are repeated for each sequential frame of the multiplicity.

15. The method according to claim 14, wherein lumen-intima and media adventitia interfaces define a brightness transition.

16. The method according to claim 15, further comprising:

for each frame, automatically marking a plurality of pixel locations corresponding to the lumen-intima and media adventitia interfaces;

fitting the plurality of pixel locations, for each one of the lumen-intima and media adventitia interface edges, with a curve, the curve mathematically describing the lumen-intima and media adventitia interfaces edges; and

defining pairs of pixel points corresponding to vertically opposed pixel locations, each pixel pair defining a separation distance between the lumen-intima interface and the media-adventitia interface.

17. The method according to claim 16, wherein the marking, fitting and defining steps are performed on a far wall portion of a standardized segment of a common carotid artery, and wherein the marking, fitting and defining steps are performed on a near wall portion of said standardized segment of a common carotid artery, and wherein the marking, fitting and defining steps are repeated for each sequential frame of the multiplicity.

18. The method according to claim 17, wherein the pixel point pairs, for each frame, are used to determine an intima-media thickness measurement and an arterial diameter measurement.

19. The method according to claim 18, further comprising:

plotting an intima-media thickness measurement for each frame in sequence;

plotting an arterial diameter measurement for each frame in sequence;

identifying a minimum arterial diameter from the plotted arterial diameter measurements; and

identifying a maximum arterial diameter from the plotted arterial diameter measurements.

20. The method according to claim 19, wherein intima-media thickness is determined at a frame time corresponding to both the minimum and maximum arterial diameters.

21. The method according to claim 20, wherein the standardized arterial segment is defined in relation to a standard arrangement and orientation of a set of anatomical landmark structures, including a visualization of a jugular vein stacked above a carotid artery in a region proximate the carotid bulb.

22. An automated method for obtaining vascular properties measurements from multiple, sequential ultrasound image frames, the method comprising:

obtaining ultrasound images from a standardized region of a common carotid artery, the images characterized as a multiplicity of digitized sequential image frames taken over at least two cardiac cycles;

establishing a standardized scale within the region, the scale having a predetermined size characterized by a number of image pixels;

automatically identifying a lumen-intima interface edge in a wall portion of the artery;

automatically identifying a media adventitia interface edge in the wall portion;

storing a representation of the identified lumen-intima and media adventitia interfaces;

displaying a subsequent digitized sequential frame on the display; and

automatically establishing approximate boundary locations of the lumen-intima and media adventitia interfaces of the subsequent frame on the basis of the automatically identified lumen-intima and media adventitia interface edges of the first frame.

23. The method according to claim 22, further comprising:

automatically marking a plurality of pixel locations corresponding to the lumen-intima and media adventitia interfaces along the standardized scale; and

fitting the plurality of pixel locations, for each one of the lumen-intima and media adventitia interface edges, with a curve, the curve mathematically describing the lumen-intima and media adventitia interfaces edges.

24. The method according to claim 23, wherein the marking and fitting steps are performed on a far wall portion of the standardized region, and wherein the marking and fitting steps are performed on a near wall portion of said standardized region of the common carotid artery, and wherein the marking and fitting steps are repeated for each sequential frame of the multiplicity.

25. The method according to claim 24, wherein the curve describing the lumen-intima and media adventitia interfaces edges for a frame defines guidance points for the marking and fitting steps on an immediately subsequent frame.

26. The method according to claim 25, wherein the marking and fitting steps are adaptively performed on a subsequent frame on the basis of the curve fit on the immediately preceding frame.

27. The method according to claim 26, wherein pixel coordinate location values defined by the mathematical curve are evaluated against corresponding actual pixel coordinate values determined by the marking step, coordinate location values defined by the mathematical curve being chosen as a guidance point for a corresponding pixel location on a subsequent frame if the deviation of the actual pixel coordinate from the corresponding curve coordinate exceeds a predetermined value.

28. The method according to claim 27, wherein the curve is a least square fit to the automatically marked plurality of pixel locations.

专利名称(译)	用于超声图像采集和多帧数据处理的分屏显示系统和标准化方法		
公开(公告)号	US20040116813A1	公开(公告)日	2004-06-17
申请号	US10/319411	申请日	2002-12-13
[标]申请(专利权)人(译)	塞尔泽罗伯特· HODIS HOWARDñ		
申请(专利权)人(译)	塞尔泽罗伯特H. HODIS霍华德N.		
当前申请(专利权)人(译)	塞尔泽罗伯特H. HODIS霍华德N.		
[标]发明人	SELZER ROBERT H HODIS HOWARD N		
发明人	SELZER, ROBERT H. HODIS, HOWARD N.		
IPC分类号	A61B8/08 A61B8/12		
CPC分类号	A61B5/02007 A61B8/485 A61B8/463 A61B8/0858		
其他公开文献	US7927278		
外部链接	Espacenet USPTO		

摘要(译)

标准化的采集方法使用分屏显示器帮助操作者精确复制通过几次间隔检查获得的高分辨率B模式超声图像，其中来自早期检查的动脉超声图像显示在屏幕的一侧而实际上是真实的来自当前检查的时间“实时”超声图像显示在屏幕另一侧的较早图像旁边。通过同时或交替地观察两个图像，同时手动调节超声换能器，操作者能够看到与早期超声检查中的所选图像最佳匹配的实时图像。利用该方法，在连续图像帧上的标准区域中测量动脉结构的动态材料特性，例如IMT和直径。通过使用紧接在前帧的真实回波边缘坐标作为初始边界条件，序列的每个帧具有其自动确定的回波边缘边界。计算机化的回波边缘识别和多个连续图像帧的跟踪增强了动脉直径和IMT的测量，并允许改进的血管尺寸测量，包括血管硬度和IMT测定。

