



- (51) International Patent Classification:
A61B 5/055 (2006.01) A61B 5/00 (2006.01)
A61B 5/0205 (2006.01)
- (21) International Application Number:
PCT/US2015/030015
- (22) International Filing Date:
8 May 2015 (08.05.2015)
- (25) Filing Language: English
- (26) Publication Language: English
- (30) Priority Data:
61/990,776 9 May 2014 (09.05.2014) US
- (71) Applicant: THE REGENTS OF THE UNIVERSITY OF CALIFORNIA [US/US]; 1111 Franklin Street, 12th Floor, Oakland, California 94607-5200 (US).
- (72) Inventors: FINN, J. Paul; University of California, Los Angeles, Department of Radiological Sciences, Box 951721, Los Angeles, California 90095-1721 (US). HU, Peng; University of California, Los Angeles, Department of Radiological Sciences, Box 951721, Los Angeles, California 90095-1721 (US). HAN, Fei; University of California, Los Angeles, Department of Radiological Sciences, Box 951721, Los Angeles, California 90095-1721 (US).

(74) Agent: O'BANION, John; O'Banion & Ritchey LLP, 400 Capitol Mall, Suite 1550, Sacramento, California 95814 (US).

(81) Designated States (unless otherwise indicated, for every kind of national protection available): AE, AG, AL, AM, AO, AT, AU, AZ, BA, BB, BG, BH, BN, BR, BW, BY, BZ, CA, CH, CL, CN, CO, CR, CU, CZ, DE, DK, DM, DO, DZ, EC, EE, EG, ES, FI, GB, GD, GE, GH, GM, GT, HN, HR, HU, ID, IL, IN, IR, IS, JP, KE, KG, KN, KP, KR, KZ, LA, LC, LK, LR, LS, LU, LY, MA, MD, ME, MG, MK, MN, MW, MX, MY, MZ, NA, NG, NI, NO, NZ, OM, PA, PE, PG, PH, PL, PT, QA, RO, RS, RU, RW, SA, SC, SD, SE, SG, SK, SL, SM, ST, SV, SY, TH, TJ, TM, TN, TR, TT, TZ, UA, UG, US, UZ, VC, VN, ZA, ZM, ZW.

(84) Designated States (unless otherwise indicated, for every kind of regional protection available): ARIPO (BW, GH, GM, KE, LR, LS, MW, MZ, NA, RW, SD, SL, ST, SZ, TZ, UG, ZM, ZW), Eurasian (AM, AZ, BY, KG, KZ, RU, TJ, TM), European (AL, AT, BE, BG, CH, CY, CZ, DE, DK, EE, ES, FI, FR, GB, GR, HR, HU, IE, IS, IT, LT, LU, LV, MC, MK, MT, NL, NO, PL, PT, RO, RS, SE, SI, SK, SM, TR), OAPI (BF, BJ, CF, CG, CI, CM, GA, GN, GQ, GW, KM, ML, MR, NE, SN, TD, TG).

Declarations under Rule 4.17:

— as to the applicant's entitlement to claim the priority of the earlier application (Rule 4.17(iii))

[Continued on next page]

(54) Title: CARDIAC PHASE-RESOLVED NON-BREATH-HOLD 3-DIMENSIONAL MAGNETIC RESONANCE ANGIOGRAPHY

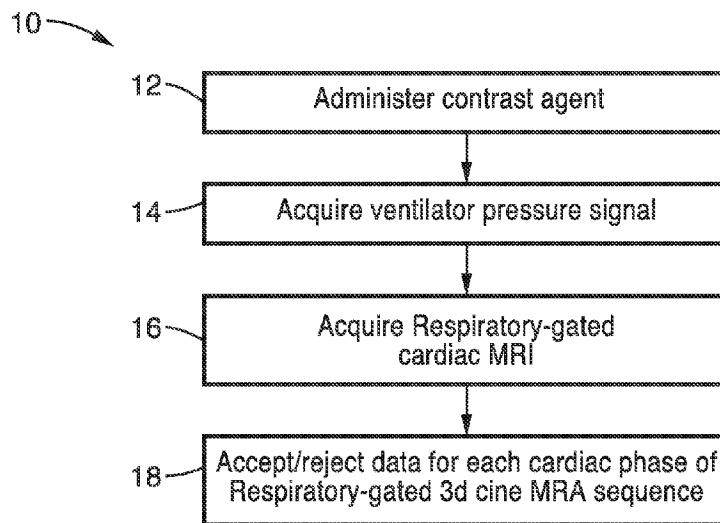



FIG. 1

(57) Abstract: 3D cine MR angiography systems and methods are disclosed for use during the steady state intravascular distribution phase of ferumoxytol. The 3D cine MRA technique enables improved delineation of cardiac anatomy in pediatric patients undergoing cardiovascular MRI.



Published:

— with international search report (Art. 21(3))

**CARDIAC PHASE-RESOLVED NON-BREATH-HOLD
3-DIMENSIONAL MAGNETIC RESONANCE ANGIOGRAPHY**

CROSS-REFERENCE TO RELATED APPLICATIONS

5 **[0001]** This application claims priority to, and the benefit of, U.S. provisional patent application serial number 61/990,776 filed on May 9, 2014, incorporated herein by reference in its entirety.

STATEMENT REGARDING FEDERALLY SPONSORED
RESEARCH OR DEVELOPMENT

10 **[0002]** Not Applicable

INCORPORATION-BY-REFERENCE OF
COMPUTER PROGRAM APPENDIX

15 **[0003]** Not Applicable

NOTICE OF MATERIAL SUBJECT TO
COPYRIGHT PROTECTION

20 **[0004]** A portion of the material in this patent document is subject to copyright protection under the copyright laws of the United States and of other countries. The owner of the copyright rights has no objection to the facsimile reproduction by anyone of the patent document or the patent disclosure, as it appears in the United States Patent and Trademark Office publicly available file or records, but otherwise reserves all copyright rights
25 whatsoever. The copyright owner does not hereby waive any of its rights to have this patent document maintained in secrecy, including without limitation its rights pursuant to 37 C.F.R. § 1.14.

BACKGROUND

30 **[0005]** 1. Technical Field

[0006] This invention pertains generally to angiography, and more particularly to 3D magnetic resonance imaging angiography.

[0007] 2. Background Discussion

[0008] Contrast-enhanced magnetic resonance angiography (CE-MRA) is particularly appealing for evaluating patients with cardiovascular disorders due to concerns associated with alternative imaging modalities, including repeated exposure to ionizing radiation, invasive catheterization and the use of iodinated contrast agents. Detailed delineation of the vascular anatomy provided by CE-MRA is important for planning surgical or catheter interventions.

[0009] Conventional breath-hold first-pass CE-MRA provides diagnostic visualization of the majority of extra-cardiac vessels. However, first-pass CEMRA is generally applied without cardiac gating and provides limited or poor definition of intra-cardiac anatomy, e.g. ventricular outflow tracts, cardiac chambers and coronary anatomy, such that supplemental 2-D cardiac cine MRI is usually required. Cardiac gated 3D CEMRA has been described previously, but the requirement to image the first pass of a contrast bolus in a breath-hold has imposed restrictions on temporal resolution, spatial resolution and anatomic coverage, relative to their non-gated counterparts.

[0010] Furthermore, patients younger than 6 years old are generally unable to cooperate with breath-hold instructions. Therefore, in several institutions, general anesthesia and mechanical ventilation are preferred in these young patients where a controlled breath-hold is achieved by temporarily pausing the MR-compatible ventilator. Breath holding is repeated for several temporal phases of contrast enhancement and also for multiple, individual cardiac cine acquisitions. For the vast majority of patients, controlled apnea is a very safe procedure when carried out by specialist anesthesiologists or neonatal intensive care unit (NICU) staff. Nonetheless, in sick infants and neonates with complex congenital heart disease (CHD), it is desirable to minimize the frequency and duration of breath holding, while at the same time providing sufficiently detailed anatomic and functional evaluation of the heart and great vessels to guide patient management.

[0011] Moreover, in infants and patients with severe renal impairment,

concerns about nephrogenic systemic fibrosis (NSF) and warnings from the Food and Drug Administration (FDA) have caused referring physicians to shy away from the use of GBCAs.

[0012] CE-MRA is typically performed within a breath-hold of 20-25

5 seconds during first pass of a gadolinium based contrast agent (GBCA). Due to the limitation in breath-hold time and first-pass of the contrast agent, these acquisitions are generally not gated to cardiac ECG signal and those that are gated sample only a single phase of the cardiac cycle. As a result, the conventional CE-MRA falls short in providing detailed definition of intra-
10 cardiac anatomy, such as the cardiac chambers, the coronary blood vessels, the valves, etc. This is particularly limiting for children with congenital heart diseases, where high resolution imaging of anatomy and function is crucial.

[0013] For example, patients younger than 6 years old are generally unable

15 to cooperate with breath-hold instructions. Therefore, general anesthesia and mechanical ventilation are preferred in these young patients where a controlled breath-hold is achieved by temporarily pausing the MR-compatible ventilator. Breath holding is repeated for several temporal phases of contrast enhancement and also for multiple, individual cardiac
20 cine acquisitions. For the majority of patients, controlled apnea is a safe procedure when carried out by specialist anesthesiologists or neonatal intensive care unit (NICU) staff. Nonetheless, in sick infants and neonates with complex congenital heart disease (CHD), it is desirable to minimize the frequency and duration of breath holding, while at the same time providing
25 sufficiently detailed anatomic and functional evaluation of the heart and great vessels to guide patient management.

BRIEF SUMMARY

[0014] An aspect of the present description is cardiac phase-resolved non-

30 breath-hold 3D magnetic resonance angiography that is performed during the steady state distribution phase of intravascular contrast agents, such as ferumoxytol. This provides highly detailed definition for both intra-cardiac

and extra-cardiac anatomy that has not been possible using the conventional breath-held first-pass contrast-enhanced MRA techniques.

[0015] In one aspect, the use of ferumoxytol as an intravascular contrast agent, in conjunction with a 3D cine MRA sequence and ventilator respiratory gating, enables high quality delineation of cardiovascular anatomy beyond what is currently possible using conventional cardiovascular MRI in pediatric patients.

[0016] The data acquisition methods of the present description may be performed without the need for breath holding, because the concentration of the intravascular contrast agent, such as ferumoxytol, is highly stable within the blood pool, once the steady state distribution phase has been established. This is in sharp distinction to the case with the conventional gadolinium based extracellular contrast agents, which are eliminated rapidly by the kidneys and are also diluted by distribution into the expansive extracellular fluid space. These attributes of the extracellular contrast agents limit their useful angiographic time window to the first-pass and very early distribution phases.

[0017] One particular embodiment is a use case for pediatric patients who are referred for cardiac MRI under general anesthesia with controlled mechanical ventilation. In this scenario, the respiratory rate and rhythm are regular and controlled and data acquisition is performed using, for example, the ventilator airway pressure signal as a respiratory motion gating signal. Other tools to exploit the regularity of the ventilator respiratory pattern can readily be used.. Without the need for breath-holding or the need to acquire data during the first-pass of the contrast agent, the acquisition can last several minutes while it is gated, not just to the respiratory signal but also to the cardiac ECG signal. Hence it is a segmented acquisition analogous to traditional cardiac cine MRI and can be used to provide not just anatomic information, but also dynamic, functional imaging of the heart in three dimensions, with the capability to reformat planes in any orientation and with unprecedented spatial resolution for a cardiac cine study.

[0018] Further aspects of the technology will be brought out in the following

portions of the specification, wherein the detailed description is for the purpose of fully disclosing preferred embodiments of the technology without placing limitations thereon.

5 BRIEF DESCRIPTION OF THE SEVERAL VIEWS
OF THE DRAWING(S)

[0019] The technology described herein will be more fully understood by reference to the following drawings which are for illustrative purposes only:

10 [0020] FIG. 1 shows a flow diagram illustrating the respiratory-gated 3D CINE MRA method of the present description.

[0021] FIG. 2 is a schematic system diagram of the respiratory-gated 3D CINE MRA system of the present description.

15 [0022] FIG. 3 is a schematic diagram illustrating the respiratory-gated 3D CINE MRA sequence utilizing the airway pressure signal for respiratory gating in accordance with the present description.

[0023] FIG. 4 shows images of conventional breath-hold first-pass CE-MRA vs. proposed respiratory-gated 3D cine MRA (phase #3 is chosen out of 5 cardiac phases for display) of a 4-year-old, 10kg boy.

20 [0024] FIG. 5 shows reformatted cardiac four chamber view images based on the 3D cine MRA performed on a 3-day-old patient in accordance with the present disclosure.

25 [0025] FIG. 6A through FIG. 6C are images illustrating a comparison of first-pass (FIG. 6A), 3D cine MRA (FIG. 6B), and delayed phase breath-held MRA (FIG. 6C) acquired from a 3-year-old 14kg girl with an aneurysmal pulmonary artery.

30 [0026] FIG. 7A through FIG. 7C show images of all three major branches of the coronary artery (left anterior descending (FIG. 7A), left circumflex (FIG. 7B) and right coronary arteries FIG. 7C) clearly visualized by reformatting the 3D cine MRA data acquired in an 8-month-old 7kg boy with 0.9 mm isotropic resolution.

[0027] FIG. 8A and FIG. 8B show plots and corresponding images illustrating vessel sharpness measurements for lines crossing the

ascending aorta and left ventricle in corresponding left ventricle and aorta images.

DETAILED DESCRIPTION

5 **[0028]** FIG. 1 shows a flow diagram illustrating the respiratory-gated 3D CINE MRA method 10 of the present description. The method may be implemented via a respiratory-gated 3D CINE MRA system 50 as illustrated in FIG. 2. First, the contrast agent 74 is administered to the patient 72 at step 12. As will be explained in further detail below, the contrast agent 74
10 preferably comprises a specifically selected agent having a high T1 relaxivity, long intra-vascular half-life, and is not readily eliminated (e.g. by normal kidney function).

[0029] Next, at step 14, a ventilator airway pressure signal 68 is acquired from respiratory support device 66 (e.g. ventilator or the like). In one
15 embodiment, the air pressure signal 68 may be tapped into a respiratory circuit (not shown) in the mechanical ventilatory support device 66 via a 3-way stop-cock 64 and fed in real time into the MR scanner 60 (e.g. the scanner's physiological monitoring unit) for respiratory gating. Thus 3D MRA sequence data 62 acquisition may be performed at step 16 using the
20 ventilator air way pressure signal 68 as a respiratory motion gating signal. Without the need for breath-holding or the need to acquire data during the first-pass of the contrast agent 74, the acquisition can last several minutes while it is gated, not just to the respiratory signal 68 but also to the cardiac ECG signal. The other limb of the stop-cock 64 may be input to an end-tidal
25 CO₂ monitor 70 (e.g. InVivo Research, Orlando, FL).

[0030] Next at step 18, the acquired data is accepted or rejected for each cardiac phase of the respiratory-gated 3D CINE MRA sequence, as shown in more detail below with respect to FIG. 3. Programming for executing steps 14 through 16 may be performed via internal processing on the MR scanner 60, or a dedicated computer 52 having application software 54
30 stored in memory 56 for execution on processor 58.

[0031] In a preferred embodiment, the contrast agent 74 comprises

ferumoxytol. Ferumoxytol is an ultra-small super-paramagnetic iron oxide (USPIO) particle, marketed in the U.S. as Feraheme (AMAG Pharmaceuticals, Cambridge, MA) and approved by the U.S. FDA as an iron supplement for patients with chronic kidney disease. Aside from its use as an iron supplement, ferumoxytol has excellent potential as a diagnostic imaging agent due to several desirable properties. First, it has much higher T1 relaxivity ($r_1=15.7 \text{ mM}^{-1}\text{second}^{-1}$ at 1.5 tesla) compared to conventional extracellular GBCA. Second, due to its larger particle size, it is a blood pool contrast agent with an intravascular half-life of 10-14 hours. In addition, unlike GBCA, the particles are not eliminated by the kidney and are not known to be associated with NSF, making it an excellent alternative to GBCA for patients with impaired kidney function. While ferumoxytol is a preferred agent, it is appreciated that other agents, (e.g. GBCAs) may also be implemented where appropriate.

[0032] The technology described herein provides a technique that exploits the intravascular temporal stability and relaxivity of ferumoxytol in children, without the need for breath-holding. By acquiring high-resolution data in multiple phases of the cardiac cycle, structures within and around the heart, which are typically subject to motion degradation in un-gated acquisitions, are clearly defined with the systems and methods of the present description. The 3D cine MRA data 62 thereby acquired via the systems and methods of the present description may be used to support detailed visualization of intra-cardiac anatomy and dynamics in arbitrary planes.

[0033] FIG. 3 shows a schematic diagram illustrating the respiratory-gated 3D CINE MRA sequence 100 utilizing the airway pressure signal 102 for respiratory gating in accordance with the present description. The decision of accepting or rejecting data is made for each cardiac phase (Phs) of the respiratory-gated 3D CINE MRA sequence 100 (shown in FIG. 3 with 6 phases per heartbeat (HB), instead of each R-R interval, yielding improved gating efficiency. FIG. 3 shows a piece of the actual ventilator pressure signal 102 and data acquisition timing recorded from an exemplary subject patient. In this example, Phs4-6 in HB1 and Phs1-2 in HB2 were rejected

because the ventilator pressure registered above the gating threshold. Phs3 in HB2 was also rejected because the same data has already been acquired in the first heartbeat. The accepted data in HB1 and HB2 is combined as a complete segment (Segment 1), even though neither HB is completely within the respiratory gating window. The gating efficiency in this example was 60% (3 out of 5 heartbeats) although only 1 heartbeat was entirely within the respiratory gating window.

[0034] The sequence 100 of FIG. 3 is configured as a high bandwidth, 3D, ECG-triggered spoiled gradient echo sequence. The 3D data acquisition is configured such that k-space is segmented in a fashion analogous to 2D cardiac cine MRI, whereby 5-8 independent temporal phases (6 shown in FIG. 3) are acquired within the cardiac cycle. Instead of accepting or rejecting data for the entire R-R interval as previously proposed, the gating acceptance/rejection decision in step 18 is made for each individual cardiac phase to improve the gating efficiency, as shown in FIG. 3.

[0035] Although the systems and methods disclosed herein are primarily directed to cardiac MRI for pediatric patients under general anesthesia and controlled mechanical ventilation, it is appreciated that the techniques disclosed herein may be implemented for other patients (pediatric or adult) who undergo cardiac MRI during spontaneous breathing without general anesthesia.

[0036] Example 1

[0037] Six patients (mean age 2.4 ± 2.1 y.o., range 3 days to 5 years, 4 male) underwent cardiovascular MRI with controlled mechanical ventilation. Conventional breath-held contrast-enhanced MRA (CE-MRA) was performed during the first-pass in comparison to delayed steady state distribution phases of ferumoxytol, which was used in place of gadolinium based contrast agents (GBCA).

[0038] Four patients underwent general anesthesia and 2 patients were transferred already intubated from the neonatal intensive care unit (NICU) and the patients were monitored by pediatric anesthesiologists or NICU staff respectively, who monitored the patients continuously throughout the

imaging exam. As appropriate, anesthesia was maintained with inhalation of a mixture of oxygen and savoflurane and patients from the NICU were sedated with fentanyl. In all cases, 0.2 mg/kg of Rocuronium Bromide was administrated as a muscle relaxant. An MR compatible ventilator (Fabius MRI, Drager Medical, Telford, PA) was used with positive end expiratory pressure (PEEP) in select cases as considered clinically appropriate. Standard physiologic monitoring was performed (ECG, pulse oximetry, blood pressure and end-tidal C_{O2} level) with an MR compatible monitoring system (InVivo Research, Orlando, FL).

5
10 **[0039]** All studies were performed on a clinical whole body 3T MRI scanner (Magnetom TIM Trio, Siemens Medical Solutions). Receiver coil configurations were customized to patient size and included adult knee coil, head coil, flex coil or body array coil and these were combined if appropriate, depending on the size of the subject to provide optimal coverage.

15 **[0040]** For each patient, ferumoxytol was administered to a dose of 4 mg/kg of iron. The product formulation was diluted to a volume such that the infusion period was 15 seconds at the flow rate considered appropriate for patient size (0.3-1.0 ml/s). A small timing bolus containing 0.5 mg/kg iron was first injected to determine the delay time between injection and the arrival of contrast in the region of interest, similar to a conventional timing test injection with GBCAs. After the correct timing for the first-pass CE-MRA sequence was obtained, the remaining bolus was injected at the rate of 0.3-1.0 ml/s (adjusted based on the patient size) followed by a bolus of saline administered at the same infusion rate. A first-pass CE-MRA acquisition spanning an 18-22 second breath-hold was performed. Subsequently, the same acquisition was repeated during the delayed venous phase of ferumoxytol.

25 **[0041]** Parameters for first-pass and delayed phase CE-MRA were as follows: TR/TE=2.9/0.9 ms; flip angle, 15°; in-plane resolution, 0.9-1.2 mm; slice thickness, 1.1-1.5 mm; GRAPPA acceleration 3X-4X. Partial Fourier acquisition was used for in-plane and through-plane phase encoding

directions. The ventilator gated, 3D-cine MRA acquisition was started during the steady state distribution phase of ferumoxylol, 3-5 minutes following the first pass acquisition. Depending on the patient's heart rate, 5-8 cardiac phases were acquired. The respiratory gating window was positioned in the expiration phase and a threshold was set to 30% of the signal's dynamic range, such that data were acquired only when the airway pressure signal was below the pre-defined threshold. Sequence parameters included: TR/TE=2.9/0.9 ms; flip angle, 15°; 3D isotropic resolution, 0.6-0.9mm; GRAPPA 2X-3X and partial Fourier was used in phase encoding and partition encoding direction. For heart rates in the 110 bmp to 160 bpm range, each of the 5-8 cardiac phases was acquired within a time window of 65 ms to 95 ms.

[0042] Visual assessment of the subjective image quality was performed by two board-certified radiologists. The conventional breath-held CE-MRA images and the proposed cine CE-MRA images were presented in random order to the evaluators, who were blinded to the patient information and the imaging technique. The evaluators scored the images on a 1-4 scale (1: non-diagnostic; 2: poor definition such that only gross features such as overall patency are evaluable; 3: good definition such that pathology can be confidently visualized or excluded; 4: excellent definition such that detailed anatomy is clearly visualized with sharp borders) with respect to aortic root, pulmonary trunk, myocardium (left and right ventricles), coronary artery origin and descending aorta.

[0043] Quantitative analysis of the first-pass breath-held CE-MRA and the cine CE-MRA were performed. Signal to noise ratio (SNR) was measured as the mean signal in an ROI of the aortic arch divided by the standard deviation of an ROI of air outside of the patient's body. Sharpness was measured in the left ventricle and ascending aorta by drawing a linear signal profile and calculating the slope of the signal intensity. The slope is defined as the image intensity difference divided by the distance between the two points at 20% and 80% of the dynamic range respectively. The calculated slope on both sides was then averaged as the final sharpness

measurement.

[0044] The SNR and vessel sharpness measurements of the two images were compared using a paired t-test. The subjective image quality scores were compared using a Wilcoxon signed-rank test. For both tests, a P <0.05 is considered statistically significant.

[0045] The 3D cine CE-MRA method described herein was successfully acquired on all 6 subjects, with the scan time ranging from 3.5 minutes to 8 minutes, and the respiratory gating efficiency ranging from 45%-58%. The breath-held first-pass CE-MRA was not acquired in 2 patients, due to concerns about cardiopulmonary insufficiency.

[0046] FIG. 4 shows a comparison of two images of conventional first-pass breath-held CE-MRA (images 120 and 122) and the 3D cine MRA method of the present disclosure (images 110 and 112) as well as comparison images (124 vs. 114) for 3D volume rendering of a patient. Due to lack of cardiac gating, the anatomy of the ventricles and atria in the breath-held first-pass CE-MRA image 124 was blurred by cardiac motion, and the definition of the proximal great vessels was also compromised. However, these structures, as well the coronary arteries (and in particular the proximal coronary artery), were clearly defined (sharper vessel edges and blood-myocardium boundaries) without motion-related blurring using the 3D cine MRA generated image 114.

[0047] FIG. 5 shows reformatted cardiac four-chamber view images based on the 3D cine MRA data acquired on a 3-day-old 2 kg boy. Due to concerns about cardiopulmonary insufficiency, the attending anesthesiologist advised against breath-holding during the MRI scan. As a result, neither standard breath-hold first-pass MRA nor 2D breath-hold cardiac cine MRI was acquired on this patient. However, the ventricular anatomy, chamber size, and myocardial thickness were able to be assessed based on the 7 cardiac phases MRA images, which spanned the cardiac cycle. The cardiac chambers are well delineated for both systole and diastole phases of the cardiac cycle. Arbitrary reconstruction planes are possible without loss of resolution due to the 0.7 mm isotropic

resolution in this patient.

[0048] FIG. 6A through FIG. 6C are images illustrating a comparison of first-pass (FIG. 6A), 3D cine MRA (FIG. 6B), and delayed phase breath-held MRA (FIG. 6C) acquired on a 3-year-old 14kg girl with an aneurysmal pulmonary artery. Only one of five cardiac phases is displayed, timed during the aortic ejection period. All images were acquired after ferumoxytol injection. The diaphragm of the non-breath-held 3D cine MRA image (FIG. 6B) has a sharp border (including good delineation of the aortic valve leaflets (arrow)), confirming good respiratory gating using the ventilator signal. As seen in FIG. 6A through FIG. 6C, the cardiac chambers and great vessels, as well as the aortic valve and pulmonary artery, are visualized better using the 3D cine MRA. First-pass and delayed-phase breath-held MRA images (FIG. 6A and FIG. 6C) show blurring of the heart and proximal great vessels (poor definition in the cardiac chambers and aortic outflow) due to cardiac motion.

[0049] The 3D isotropic resolution of the 3D cine MRA sequence allows for arbitrary multi-planar reformatting of the volume. FIG. 7A through FIG. 7C show images of all three major branches of the coronary artery (left anterior descending (LAD- FIG. 7A), left circumflex (Circ CA - FIG. 7B) and right coronary artery and aorta (RCA, Ao - FIG. 7C) clearly visualized (demonstrating excellent delineation of the left and right coronary arteries previously not possible using conventional breath-held MRA) by reformatting the 3D cine MRA data acquired in an 8-month-old 7kg boy with 0.9 mm isotropic resolution. In 5 out of the 6 patients, the origins of the coronaries, including 2 anomalous origins, were identified based on the 3D cine MRA image.

[0050] As shown in Table 1, the subjective image score of the 3D cine MRA was significantly higher than conventional first-pass MRA at coronary origin ($p=0.029$), aortic root ($p=0.001$), myocardium ($p=0.029$) and pulmonary trunk ($p=0.043$). The scores on descending aorta matched those of the first-pass MRA, although respiratory-gating, instead of breath-holding, was used in the 3D cine MRA method.

[0051] The 3D cine MRA method provided significantly higher SNR over the conventional MRA (91.4 ± 10.7 vs. 72.0 ± 10.3 , $P=0.034$). FIG. 8A and FIG. 8B illustrate how the vessel sharpness was measured on the subjects aorta and left ventricle, respectively. Images 130 and 140 show aorta and left ventricle images respectively for conventional first-pass MRA lines 136, 146. Images 132 and 142 show aorta and left ventricle images respectively for 3D cine MRA lines 134, 144. When compared with the conventional first-pass MRA, the 3D cine MRA had significantly higher (better) vessel sharpness measurements at ascending aorta ($P=0.005$) and the LV ($P=0.002$).

[0052] The above results suggest that, by using ferumoxytol in children of any age undergoing cardiovascular MR imaging with controlled ventilation, it is feasible to acquire detailed, high resolution cine MR angiograms without the need for breath holding. In our initial study, the quality of the gated cine MR angiograms was at least as good as the breath held angiograms for vascular structures that do not undergo cardiac related motion, and was significantly better for all structures which are subject to cardiac motion. We were able to resolve cardiac and vascular anatomy with sub-millimeter isotropic resolution in multiple cardiac phases, sufficient for routine detection of coronary anatomy in patients as small as 2.5 kg.

[0053] Improved image quality compared to traditional CE-MRA approaches was realized via a combination of one or more of the following: 1) Ferumoxytol was used as an intravascular contrast agent, which relaxes the requirement for "first-pass" acquisition and thus enables an ECG-triggered CE-MRA scan of several minutes without breath-holding. This is especially relevant for pediatric applications because typically higher spatial resolution (hence longer scan time) is required due to the smaller size of the cardiac structures and blood vessels; 2) The ventilator circuit pressure signal served as an excellent surrogate of respiratory motion. As the patients in our study were undergoing mechanical ventilatory support, issues associated with traditional respiratory gating strategies during voluntary free-breathing are avoided, including the issue of irregular

respiratory motion and drifts in the gating window; 3) the 3D cine CE-MRA sequence significantly reduced cardiac motion related blurring that is typical in standard breath-held non-cardiac-gated CE-MRA. This allowed delineation of the cardiac chambers, coronary arteries, and myocardial wall with details that were previously not possible using standard CE-MRA techniques. For pediatric patients with CHD, detailed evaluation of these structures is often crucial for the purpose of surgical planning as well as post-surgical evaluation.

[0054] Ferumoxytol, approved by the FDA for parenteral treatment of iron deficiency in chronic kidney disease patients, was shown to be a promising MRI contrast agent. The systems and methods of the present disclosure exploit the advantage of its long and stable intravascular residence time, which supports a prolonged MRA scan with motion compensation techniques during the steady-state. Furthermore, for CHD patients, it may be desirable to perform cardiovascular MRI shortly after birth. It has been reported that the glomerular filtration rate (GFR) of pre-term and term newborns can be as low as $40 \text{ ml/min/1.73m}^2$, and it gradually increases to $66 \text{ ml/min/1.73m}^2$ at 2 weeks after birth. For this reason, FDA advises against the use of GBCA in neonates due to concerns associated with nephrogenic systemic fibrosis. In this regard, ferumoxytol is a potential alternative MRI contrast agent for neonates.

[0055] Although the T1 relaxivity of ferumoxytol is several times higher than typical GBCA, and comparable with gadofosveset trisodium (Ablavar, Bayer Schering Pharma, Germany) in the blood pool, it has a strong T2 relaxivity ($83 \text{ mM}^{-1} \text{ second}^{-1}$ at 1.5 tesla) that is much higher than typical GBCA. In order to minimize the potential signal loss due to T2 relaxation, we used a strong partial-echo readout in our study to achieve a much shorter echo time ($TE=0.9 \text{ ms}$). In addition to the shorter echo time, the contrast dose is chosen carefully to maximize the contrast enhancement as the signal intensity is jointly determined by the T1 shortening effect, which enhances signal, and the T2 shortening effect, which reduces signal. In one exemplary case, 4 mg/kg (0.07 mol/kg) of iron was found to provide

satisfactory results for both first-pass and steady-state CE-MRA, although in this preliminary report we did not address contrast dose optimization.

5 **[0056]** The above quantitative measurement results suggest that the proposed cine CEMRA method has improved SNR over conventional first-pass CE-MRA even though a smaller voxel size is used. This is mostly because the proposed method is not limited to a breath-hold time window, and thus a longer scan time was used. In addition, the aforementioned T2 shortening effect of ferumoxytol might indirectly influence SNR using the described approach since the peak contrast agent concentration during the 10 first-passage might cause signal loss due to enhanced T2 relaxation, offsetting the effect of the T1 shortening on signal in the standard breath-held CE-MRA. During steady state, which is when we acquired the gated cine CEMRA, the intravascular iron concentration, although stable, is lower than during the arterial first pass.

15 **[0057]** The ventilator gating approach detailed above is primarily directed to patients under general anesthesia or already intubated in the intensive care unit. However, the 3D cine CE-MRA acquisition systems and methods using ferumoxytol injection in accordance with the present disclosure can potentially be applied to patients during free-breathing using other forms of 20 respiratory motion compensation strategies, such as diaphragm navigators, respiratory bellows or MR self-gating. It is also anticipated that a variation of the pulse sequence may be generated for pediatric patients undergoing sedation rather than general anesthesia to avoid or reduce its associated side effects and potential complications of general anesthesia.

25 **[0058]** High resolution, 3-D cine MRA in accordance with the present disclosure allows for significantly improved delineation of cardiac and central vascular anatomy in pediatric patients and has potential to supplant current techniques for anatomic and functional cardiac imaging in small children.

30 **[0059]** Example 2

[0060] Use of ferumoxytol as a contrast agent was also evaluated as a non-gadolinium alternative for high-resolution CEMRA in renal failure. 9 patients

aged 6 days to 14 years were evaluated with first pass and steady state CEMRA following ferumoxytol (Feraheme, AMAG) infusion at a dose of 0.05 mmol/kg to 0.07 mmol/kg. All patients were studied on a Siemens Magnetom TIM Trio system. Coil configurations included combinations of head-neck, body array and spine array, depending on patient size. Two patients had complex congenital heart disease and 8 were being considered for organ transplantation. The patients with CHD had supplemental cardiac gated high-resolution 3D CEMRA. The imaging FOV for all sequences routinely included head, neck, thorax, abdomen and pelvis with sub-mm voxels. Multiple CEMRA phases were acquired up to 30 minutes following ferumoxytol injection and measurements of SNR and CNR in the thoracic aorta and inferior vena cava (IVC) were recorded at each phase. These were compared to similar measurements in a group of weight-matched controls examined with gadopentetate dimeglumine (Magnevist, Bayer-Schering) at 0.2 mmol /kg. Phantom measurements of T1 and T2* were made at 3.0T over a range of ferumoxytol dilution factors to include the estimated blood concentration during first pass and steady state distribution phases.

[0061] Phantom results of relaxation times at 3.0T vs. dilution factor for ferumoxytol were prepared. The T1 relaxivity of ferumoxytol in saline solution was approximately $9.0 \text{ mM}^{-1}\text{s}^{-1}$ and the T2 relaxivity was approximately $90 \text{ mM}^{-1}\text{s}^{-1}$. The estimated blood Fe concentration during first-pass was approximately 256X dilution of the stock ferumoxytol formulation and the steady state intravascular concentration was approximately 1000X dilution. The CNR measurements in the patient studies are summarized in Chart 1 for first pass, second phase and delayed phase. Two patients studied early in the series had signal loss in the aorta on first pass, felt to be due to too rapid injection resulting in T2* signal decay and this decreased the average value. Whereas in the magnevist group, aortic SNR decreased significantly over time, SNR in the ferumoxytol group remained stable to the last measurements, up to 35 minutes post injection. The stability of the vascular signal was felt to be

advantageous for the gated CEMRA acquisitions and for venous imaging.

[0062] These findings suggest that high resolution CEMRA with ferumoxytol can be successfully performed at 3.0T in pediatric patients with renal failure, eliminating concerns for NSF. Initial results are highly encouraging and compare favorably with Magnevist in controls.

[0063] Embodiments of the present technology may be described with reference to flowchart illustrations of methods and systems according to embodiments of the technology, and/or algorithms, formulae, or other computational depictions, which may also be implemented as computer program products. In this regard, each block or step of a flowchart, and combinations of blocks (and/or steps) in a flowchart, algorithm, formula, or computational depiction can be implemented by various means, such as hardware, firmware, and/or software including one or more computer program instructions embodied in computer-readable program code logic. As will be appreciated, any such computer program instructions may be loaded onto a computer, including without limitation a general purpose computer or special purpose computer, or other programmable processing apparatus to produce a machine, such that the computer program instructions which execute on the computer or other programmable processing apparatus create means for implementing the functions specified in the block(s) of the flowchart(s).

[0064] Accordingly, blocks of the flowcharts, algorithms, formulae, or computational depictions support combinations of means for performing the specified functions, combinations of steps for performing the specified functions, and computer program instructions, such as embodied in computer-readable program code logic means, for performing the specified functions. It will also be understood that each block of the flowchart illustrations, algorithms, formulae, or computational depictions and combinations thereof described herein, can be implemented by special purpose hardware-based computer systems which perform the specified functions or steps, or combinations of special purpose hardware and computer-readable program code logic means.

[0065] Furthermore, these computer program instructions, such as embodied in computer-readable program code logic, may also be stored in a computer-readable memory that can direct a computer or other programmable processing apparatus to function in a particular manner, such that the instructions stored in the computer-readable memory produce an article of manufacture including instruction means which implement the function specified in the block(s) of the flowchart(s). The computer program instructions may also be loaded onto a computer or other programmable processing apparatus to cause a series of operational steps to be performed on the computer or other programmable processing apparatus to produce a computer-implemented process such that the instructions which execute on the computer or other programmable processing apparatus provide steps for implementing the functions specified in the block(s) of the flowchart(s), algorithm(s), formula(e), or computational depiction(s).

[0066] It will further be appreciated that the terms "programming" or "program executable" as used herein refer to one or more instructions that can be executed by a processor to perform a function as described herein. The instructions can be embodied in software, in firmware, or in a combination of software and firmware. The instructions can be stored locally to the device in non-transitory media, or can be stored remotely such as on a server or all or a portion of the instructions can be stored locally and remotely. Instructions stored remotely can be downloaded (pushed) to the device by user initiation, or automatically based on one or more factors. It will further be appreciated that as used herein, that the terms processor, computer processor, central processing unit (CPU), and computer are used synonymously to denote a device capable of executing the instructions and communicating with input/output interfaces and/or peripheral devices.

[0067] From the description herein, it will be appreciated that that the present disclosure encompasses multiple embodiments which include, but are not limited to, the following:

[0068] 1. A method for magnetic resonance angiography, comprising: administering an intravascular contrast agent to a human subject; acquiring

a signal from a ventilatory support device coupled to the subject; acquiring cardiac magnetic resonance images of the subject; and respiratory gating the acquired cardiac magnetic resonance images as a function of the acquired signal.

- 5 **[0069]** 2. The method of any preceding embodiment, wherein the signal comprises a ventilator airway pressure signal.
- [0070]** 3. The method of any preceding embodiment, wherein the ventilator airway pressure signal is applied as a respiratory motion gating signal.
- [0071]** 4. The method of any preceding embodiment, wherein the cardiac
10 magnetic resonance images are acquired without breath-holding of the subject.
- [0072]** 5. The method of any preceding embodiment, wherein the cardiac magnetic resonance images are acquired during the multiple passes of the contrast agent.
- 15 **[0073]** 6. The method of any preceding embodiment, wherein the contrast agent comprises ferumoxytol.
- [0074]** 7. The method of any preceding embodiment, wherein acquiring cardiac magnetic resonance images comprises acquiring a respiratory-gated 3D CINE MRA sequence.
- 20 **[0075]** 8. The method of any preceding embodiment: wherein the respiratory-gated 3D CINE MRA sequence comprises a plurality of cardiac phases; and wherein respiratory gating the acquired cardiac magnetic resonance images comprises accepting or rejecting image data for each cardiac phase of the respiratory-gated 3D CINE MRA sequence.
- 25 **[0076]** 9. The method of any preceding embodiment, wherein the 3D CINE MRA sequence comprises an ECG-triggered spoiled gradient echo sequence.
- [0077]** 10. A system for magnetic resonance angiography, comprising: a
30 computer processor; and a memory storing instructions executable on the processor; the instructions, when executed, performing the steps comprising: acquiring a signal from a ventilatory support device coupled to a subject; acquiring cardiac magnetic resonance images of the subject; and

respiratory gating the acquired cardiac magnetic resonance images as a function of the acquired signal.

5 [0078] 11. The system of any preceding embodiment, further comprising an intravascular contrast agent configured to be administered into the human subject.

[0079] 12. The system of any preceding embodiment, wherein the signal comprises a ventilator airway pressure signal.

10 [0080] 13. The system of any preceding embodiment, wherein the ventilator airway pressure signal is applied as a respiratory motion gating signal.

[0081] 14. The system of any preceding embodiment, wherein the cardiac magnetic resonance images are acquired without breath-holding of the subject.

15 [0082] 15. The system of any preceding embodiment, wherein the cardiac magnetic resonance images are acquired during the multiple passes of the contrast agent.

[0083] 16. The system of any preceding embodiment, wherein the contrast agent comprises ferumoxytol.

20 [0084] 17. The system of any preceding embodiment, wherein acquiring cardiac magnetic resonance images comprises acquiring a respiratory-gated 3D CINE MRA sequence.

25 [0085] 18. The system of any preceding embodiment: wherein the respiratory-gated 3D CINE MRA sequence comprises a plurality of cardiac phases; and wherein respiratory gating the acquired cardiac magnetic resonance images comprises accepting or rejecting image data for each cardiac phase of the respiratory-gated 3D CINE MRA sequence.

[0086] 19. The system of any preceding embodiment, wherein the 3D CINE MRA sequence comprises an ECG-triggered spoiled gradient echo sequence.

30 [0087] 20. A system for magnetic resonance angiography, comprising: an intravascular contrast agent configured to be administered into a human subject; a ventilatory support device coupled to a subject; a computer

processor; and a memory storing instructions executable on the processor; the instructions, when executed, performing the steps comprising: acquiring a signal from a ventilatory support device; acquiring cardiac magnetic resonance images of the subject; and respiratory gating the acquired cardiac magnetic resonance images as a function of the acquired signal.

5 [0088] 21. The system of any preceding embodiment, wherein the signal comprises a ventilator airway pressure signal that is applied as a respiratory motion gating signal.

10 [0089] 22. The system of any preceding embodiment, wherein the contrast agent comprises ferumoxytol.

[0090] 23. The system of any preceding embodiment, wherein acquiring cardiac magnetic resonance images comprises acquiring a respiratory-gated 3D CINE MRA sequence.

15 [0091] 24. The system of any preceding embodiment: wherein the respiratory-gated 3D CINE MRA sequence comprises a plurality of cardiac phases; and wherein respiratory gating the acquired cardiac magnetic resonance images comprises accepting or rejecting image data for each cardiac phase of the respiratory-gated 3D CINE MRA sequence.

20 [0092] 25. The system of any preceding embodiment, wherein the 3D CINE MRA sequence comprises an ECG-triggered spoiled gradient echo sequence.

[0093] 26. A method for non-gadolinium based high-resolution CEMRA for evaluation of renal failure in a patient, comprising: administering ferumoxytol as a contrast agent into the subject, and performing high-resolution CEMRA on the patient.

25 [0094] 27. A system for non-gadolinium based high-resolution CEMRA, comprising: a ferumoxytol-based contrast agent configured to be administered into a human subject; a memory storing instructions executable on the processor; and the instructions, when executed, performing the steps comprising: acquiring high-resolution CEMRA images of the subject.

30

[0095] Although the description herein contains many details, these should not be construed as limiting the scope of the disclosure but as merely providing illustrations of some of the presently preferred embodiments. Therefore, it will be appreciated that the scope of the disclosure fully encompasses other embodiments which may become obvious to those skilled in the art.

5

[0096] In the claims, reference to an element in the singular is not intended to mean "one and only one" unless explicitly so stated, but rather "one or more." All structural, chemical, and functional equivalents to the elements of the disclosed embodiments that are known to those of ordinary skill in the art are expressly incorporated herein by reference and are intended to be encompassed by the present claims. Furthermore, no element, component, or method step in the present disclosure is intended to be dedicated to the public regardless of whether the element, component, or method step is explicitly recited in the claims. No claim element herein is to be construed as a "means plus function" element unless the element is expressly recited using the phrase "means for". No claim element herein is to be construed as a "step plus function" element unless the element is expressly recited using the phrase "step for".

10

15

Table 1
Subjective Image Quality Score

	Coronary Origin	Aortic Root	Myocardium (LV and RV)	Pulmonary Trunk	Descending Aorta
Mean ± S.D First-pass MRA	1.25±0.43	1.75±0.43	2.25±0.43	2.75±0.43	4.00±0.00
Mean ± S.D 3D cine MRA	2.83±0.69	3.33±0.47	3.67±0.47	3.80±0.40	4.00±0.00
P-value	0.029	0.001	0.029	0.043	1

CLAIMS

What is claimed is:

- 5 1. A method for magnetic resonance angiography, comprising:
administering an intravascular contrast agent to a human subject;
acquiring a signal from a ventilatory support device coupled to the subject;
acquiring cardiac magnetic resonance images of the subject; and
respiratory gating the acquired cardiac magnetic resonance images as a
function of the acquired signal.
- 10 2. A method as recited in claim 1, wherein the signal comprises a
ventilator airway pressure signal.
- 15 3. A method as recited in claim 2, wherein the ventilator airway
pressure signal is applied as a respiratory motion gating signal.
4. A method as recited in claim 1, wherein the cardiac magnetic
resonance images are acquired without breath-holding of the subject.
- 20 5. A method as recited in claim 1, wherein the cardiac magnetic
resonance images are acquired during the multiple passes of the contrast agent.
6. A method as recited in claim 1, wherein the contrast agent
comprises ferumoxytol.
- 25 7. A method as recited in claim 1, wherein acquiring cardiac magnetic
resonance images comprises acquiring a respiratory-gated 3D CINE MRA
sequence.
- 30 8. A method as recited in claim 7:
wherein the respiratory-gated 3D CINE MRA sequence comprises a
plurality of cardiac phases; and

wherein respiratory gating the acquired cardiac magnetic resonance images comprises accepting or rejecting image data for each cardiac phase of the respiratory-gated 3D CINE MRA sequence.

5 9. A method as recited in claim 8, wherein the 3D CINE MRA sequence comprises an ECG-triggered spoiled gradient echo sequence.

10 10. A system for magnetic resonance angiography, comprising:
a computer processor; and
a memory storing instructions executable on the processor;
the instructions, when executed, performing the steps comprising:
 acquiring a signal from a ventilatory support device coupled to a
subject;
 acquiring cardiac magnetic resonance images of the subject; and
15 respiratory gating the acquired cardiac magnetic resonance images
as a function of the acquired signal.

20 11. A system as recited in claim 10, further comprising an intravascular contrast agent configured to be administered into the human subject.

 12. A system as recited in claim 10, wherein the signal comprises a ventilator airway pressure signal.

25 13. A system as recited in claim 12, wherein the ventilator airway pressure signal is applied as a respiratory motion gating signal.

 14. A system as recited in claim 10, wherein the cardiac magnetic resonance images are acquired without breath-holding of the subject.

30 15. A system as recited in claim 10, wherein the cardiac magnetic resonance images are acquired during the multiple passes of the contrast agent.

16. A system as recited in claim 10, wherein the contrast agent comprises ferumoxytol.

17. A system as recited in claim 10, wherein acquiring cardiac magnetic
5 resonance images comprises acquiring a respiratory-gated 3D CINE MRA sequence.

18. A system as recited in claim 17:
wherein the respiratory-gated 3D CINE MRA sequence comprises a
10 plurality of cardiac phases; and
wherein respiratory gating the acquired cardiac magnetic resonance images comprises accepting or rejecting image data for each cardiac phase of the respiratory-gated 3D CINE MRA sequence.

19. A system as recited in claim 18, wherein the 3D CINE MRA
15 sequence comprises an ECG-triggered spoiled gradient echo sequence.

20. A system for magnetic resonance angiography, comprising:
an intravascular contrast agent configured to be administered into a human
20 subject;
a ventilatory support device coupled to a subject;
a computer processor; and
a memory storing instructions executable on the processor;
the instructions, when executed, performing the steps comprising:
25 acquiring a signal from a ventilatory support device;
acquiring cardiac magnetic resonance images of the subject; and
respiratory gating the acquired cardiac magnetic resonance images
as a function of the acquired signal.

21. A system as recited in claim 20, wherein the signal comprises a
30 ventilator airway pressure signal that is applied as a respiratory motion gating signal.

22. A system as recited in claim 20, wherein the contrast agent comprises ferumoxytol.

23. A system as recited in claim 20, wherein acquiring cardiac magnetic
5 resonance images comprises acquiring a respiratory-gated 3D CINE MRA sequence.

24. A system as recited in claim 23:
wherein the respiratory-gated 3D CINE MRA sequence comprises a
10 plurality of cardiac phases; and
wherein respiratory gating the acquired cardiac magnetic resonance images comprises accepting or rejecting image data for each cardiac phase of the respiratory-gated 3D CINE MRA sequence.

15 25. A system as recited in claim 24, wherein the 3D CINE MRA sequence comprises an ECG-triggered spoiled gradient echo sequence.

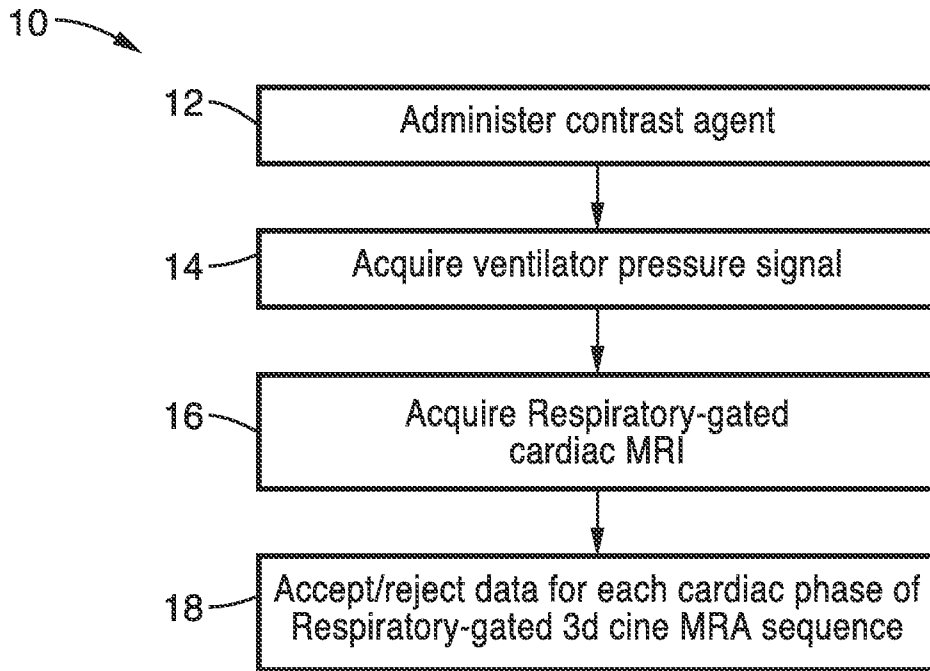


FIG. 1

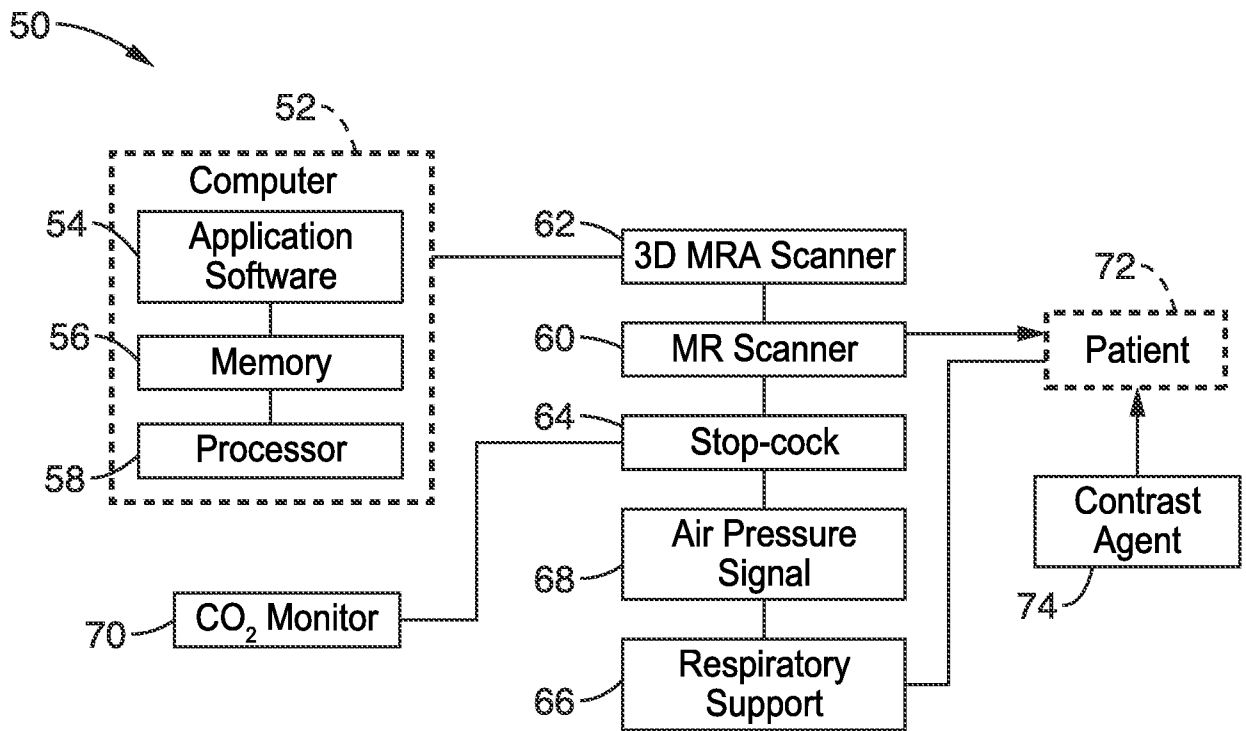


FIG. 2

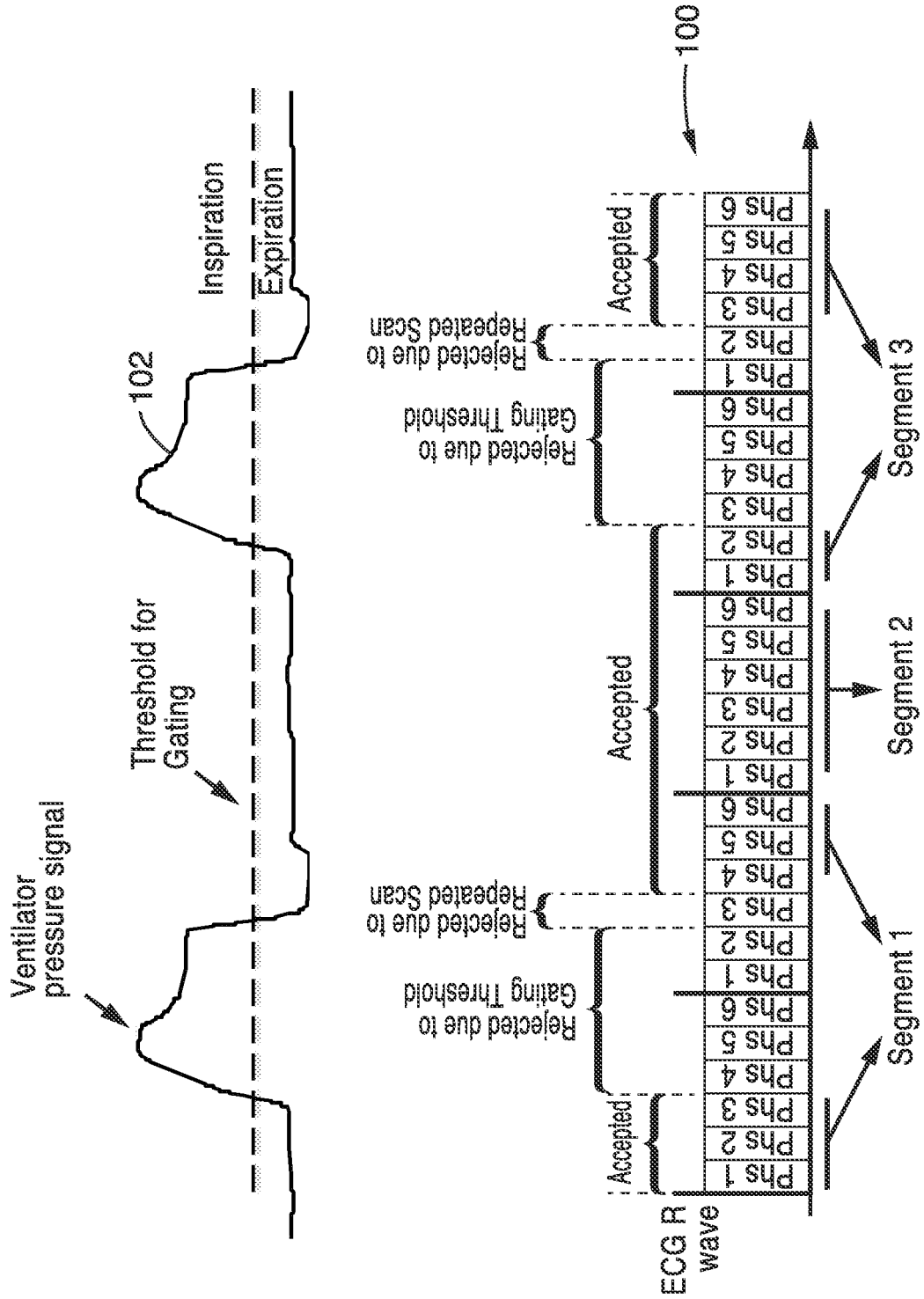


FIG. 3

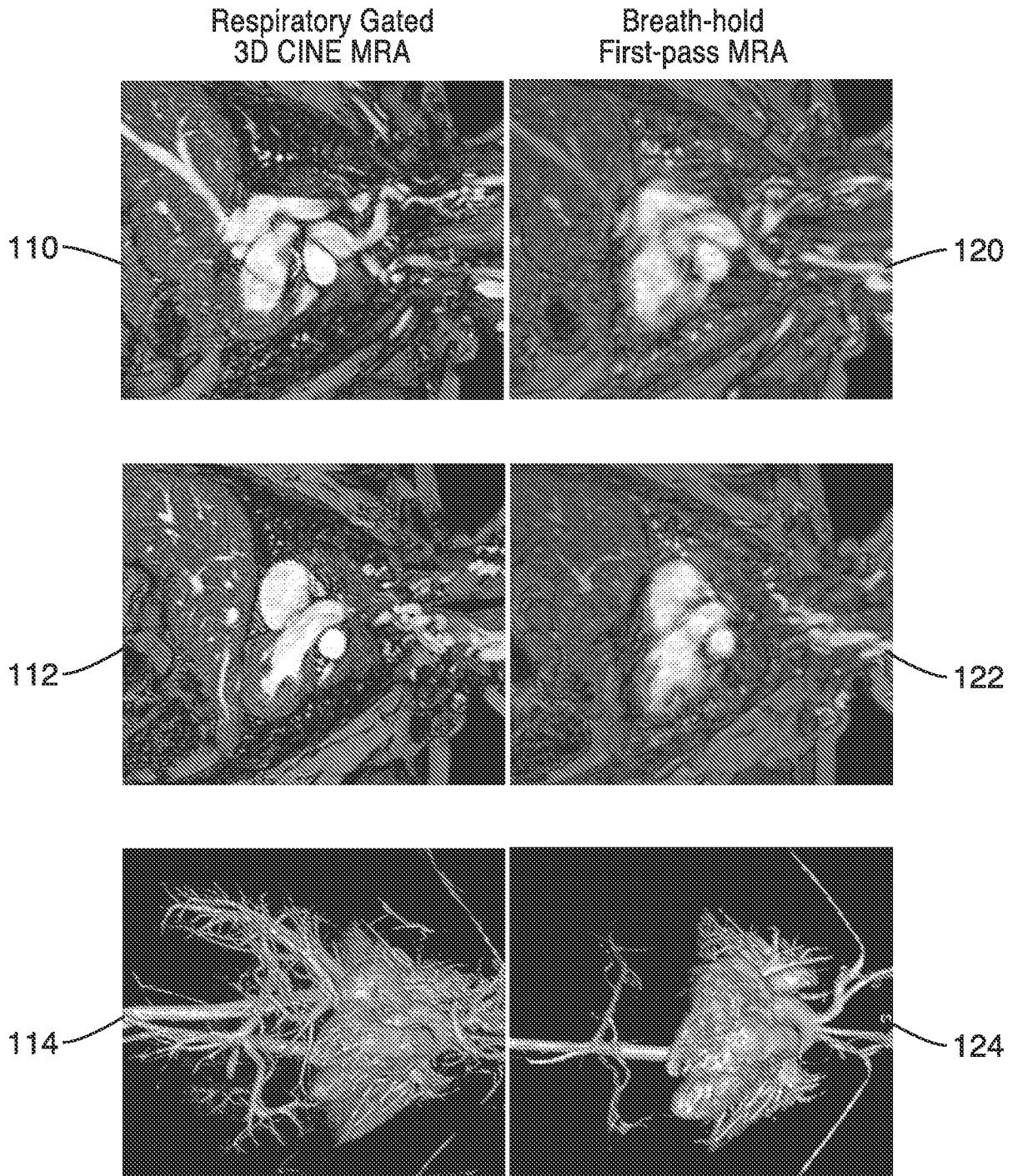


FIG. 4

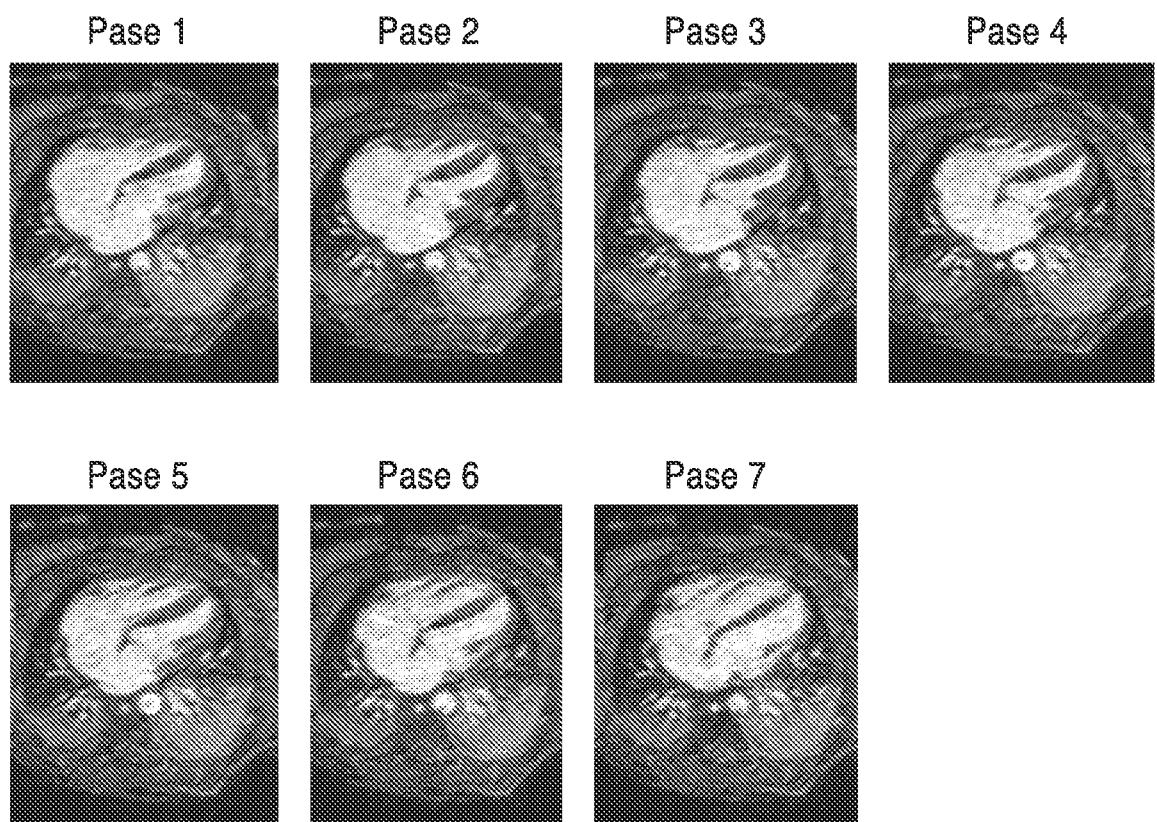


FIG. 5

First-pass
Breath-held MRA

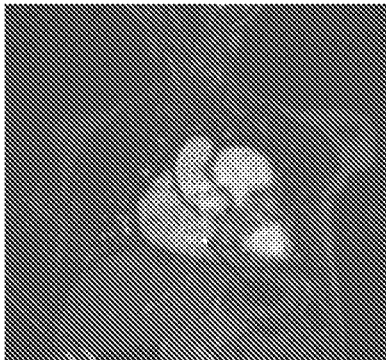

FIG. 6A

3D Cine MRA

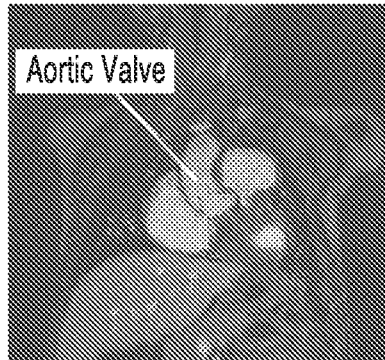


FIG. 6B

Delayed Phase
Breath-held MRA

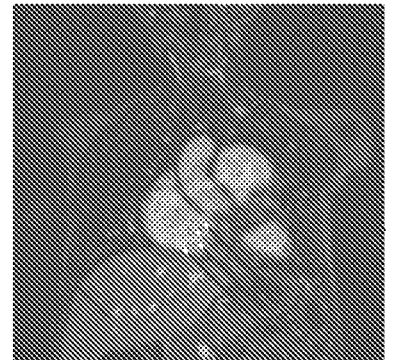

FIG. 6C

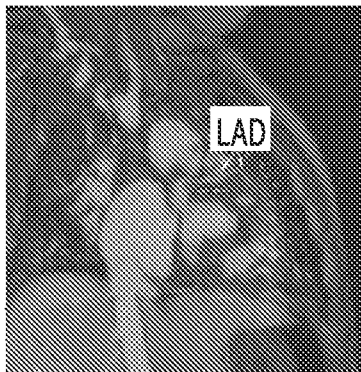


FIG. 7A

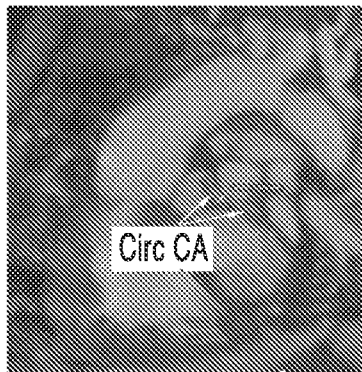


FIG. 7B

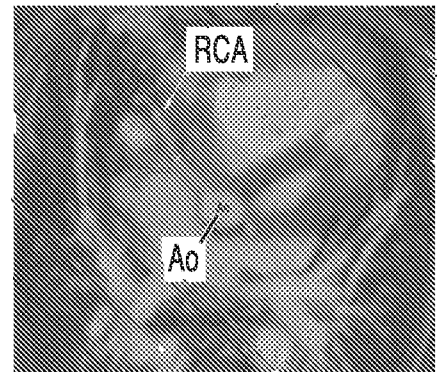


FIG. 7C

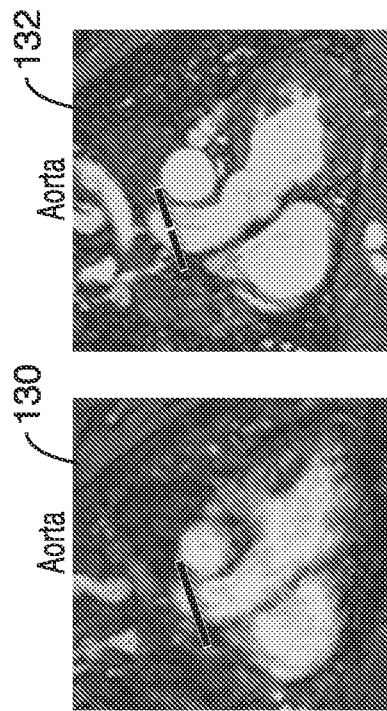
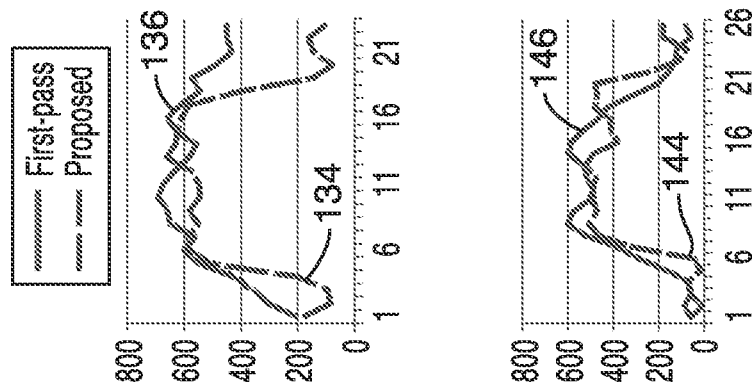


FIG. 8A

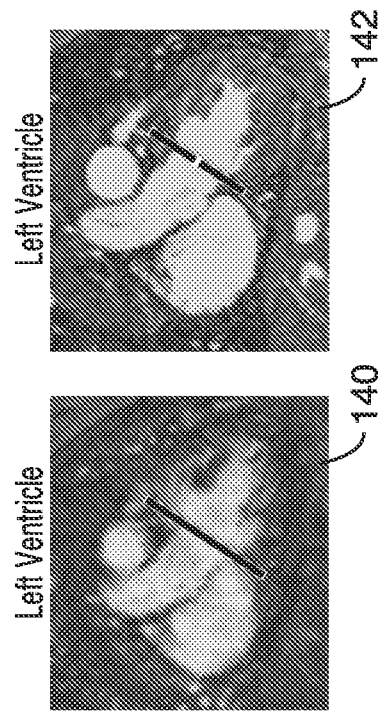


FIG. 8B

INTERNATIONAL SEARCH REPORT

International application No.
PCT/US2015/030015**A. CLASSIFICATION OF SUBJECT MATTER****A61B 5/055(2006.01)i, A61B 5/0205(2006.01)i, A61B 5/00(2006.01)i**

According to International Patent Classification (IPC) or to both national classification and IPC

B. FIELDS SEARCHED

Minimum documentation searched (classification system followed by classification symbols)

A61B 5/055; A61B 5/05; A61K 49/00; G01V 3/00; A61B 5/0205; A61B 5/00

Documentation searched other than minimum documentation to the extent that such documents are included in the fields searched

Korean utility models and applications for utility models

Japanese utility models and applications for utility models

Electronic data base consulted during the international search (name of data base and, where practicable, search terms used)

eKOMPASS(KIPO internal) & Keywords: magnetic resonance angiography, MRA, intravascular, contrast agent, ventilatory, signal

C. DOCUMENTS CONSIDERED TO BE RELEVANT

Category*	Citation of document, with indication, where appropriate, of the relevant passages	Relevant to claim No.
X	US 2005-0187464 A1 (VINCENT HO et al.) 25 August 2005 See abstract, paragraph [0048] and claims 1-17.	10, 12-14
Y		11, 15-25
Y	US 2003-0157020 A1 (STEFAN PETERSSON et al.) 21 August 2003 See abstract, paragraph [0040] and claim 1.	11, 15, 16, 20-25
Y	US 7689263 B1 (MAGGIE M. FUNG et al.) 30 March 2010 See abstract, column 2, lines 9-11, claims 1-10 and figure 1.	17-19, 23-25
A	US 2003-0233039 A1 (LINGXIONG SHAO et al.) 18 December 2003 See abstract, claims 3,5 and figure 2.	10-25
A	JP 2008-148806 A (HITACHI MEDICAL CORP.) 03 July 2008 See abstract, claims 1,6 and figures 1,2.	10-25

 Further documents are listed in the continuation of Box C. See patent family annex.

* Special categories of cited documents:

"A" document defining the general state of the art which is not considered to be of particular relevance

"E" earlier application or patent but published on or after the international filing date

"L" document which may throw doubts on priority claim(s) or which is cited to establish the publication date of another citation or other special reason (as specified)

"O" document referring to an oral disclosure, use, exhibition or other means

"P" document published prior to the international filing date but later than the priority date claimed

"T" later document published after the international filing date or priority date and not in conflict with the application but cited to understand the principle or theory underlying the invention

"X" document of particular relevance; the claimed invention cannot be considered novel or cannot be considered to involve an inventive step when the document is taken alone

"Y" document of particular relevance; the claimed invention cannot be considered to involve an inventive step when the document is combined with one or more other such documents, such combination being obvious to a person skilled in the art

"&" document member of the same patent family

Date of the actual completion of the international search

21 August 2015 (21.08.2015)

Date of mailing of the international search report

21 August 2015 (21.08.2015)

Name and mailing address of the ISA/KR

International Application Division
Korean Intellectual Property Office
189 Cheongsa-ro, Seo-gu, Daejeon Metropolitan City, 35208,
Republic of Korea

Facsimile No. +82-42-472-7140

Authorized officer

KIM, Ja Young

Telephone No. +82-42-481-8131



INTERNATIONAL SEARCH REPORT

International application No.
PCT/US2015/030015

Box No. II Observations where certain claims were found unsearchable (Continuation of item 2 of first sheet)

This international search report has not been established in respect of certain claims under Article 17(2)(a) for the following reasons:

1. Claims Nos.: 1-9
because they relate to subject matter not required to be searched by this Authority, namely:
Claims 1-9 pertain to a method for treatment of the human body by surgery or by therapy/diagnostic methods, and thus relate to a subject matter which this International Searching Authority is not required to search under PCT Article 17(2)(a)(i) and PCT Rule 39.1(iv).
2. Claims Nos.:
because they relate to parts of the international application that do not comply with the prescribed requirements to such an extent that no meaningful international search can be carried out, specifically:
3. Claims Nos.:
because they are dependent claims and are not drafted in accordance with the second and third sentences of Rule 6.4(a).

Box No. III Observations where unity of invention is lacking (Continuation of item 3 of first sheet)

This International Searching Authority found multiple inventions in this international application, as follows:

1. As all required additional search fees were timely paid by the applicant, this international search report covers all searchable claims.
2. As all searchable claims could be searched without effort justifying an additional fees, this Authority did not invite payment of any additional fees.
3. As only some of the required additional search fees were timely paid by the applicant, this international search report covers only those claims for which fees were paid, specifically claims Nos.:
4. No required additional search fees were timely paid by the applicant. Consequently, this international search report is restricted to the invention first mentioned in the claims; it is covered by claims Nos.:

- Remark on Protest**
- The additional search fees were accompanied by the applicant's protest and, where applicable, the payment of a protest fee.
 - The additional search fees were accompanied by the applicant's protest but the applicable protest fee was not paid within the time limit specified in the invitation.
 - No protest accompanied the payment of additional search fees.

INTERNATIONAL SEARCH REPORT

Information on patent family members

International application No.

PCT/US2015/030015

Patent document cited in search report	Publication date	Patent family member(s)	Publication date
US 2005-0187464 A1	25/08/2005	AU 2003-230409 A1 CA 2485490 A1 EP 1505905 A1 EP 1505905 A4 JP 2005-525864 A WO 2003-096894 A1	02/12/2003 27/11/2003 16/02/2005 25/01/2006 02/09/2005 27/11/2003
US 2003-0157020 A1	21/08/2003	AU 2001-86084 A1 CA 2417716 A1 CN 1455873 A EP 1354214 A2 JP 2004-508857 A KR 10-2003-0029983 A WO 2002-23209 A2 WO 2002-23209 A3	26/03/2002 21/03/2002 12/11/2003 22/10/2003 25/03/2004 16/04/2003 21/03/2002 22/08/2002
US 7689263 B1	30/03/2010	None	
US 2003-0233039 A1	18/12/2003	AU 2003-232400 A1 EP 1516290 A2 JP 2005-528974 A JP 4576228 B2 US 7117026 B2 WO 2003-107275 A2 WO 2003-107275 A3	31/12/2003 23/03/2005 29/09/2005 04/11/2010 03/10/2006 24/12/2003 25/03/2004
JP 2008-148806 A	03/07/2008	JP 4956170 B2	20/06/2012

专利名称(译)	心脏相位分辨非呼吸三维磁共振血管造影		
公开(公告)号	EP3139833A1	公开(公告)日	2017-03-15
申请号	EP2015789422	申请日	2015-05-08
[标]申请(专利权)人(译)	加利福尼亚大学董事会		
申请(专利权)人(译)	加利福尼亚大学董事会		
当前申请(专利权)人(译)	加利福尼亚大学董事会		
[标]发明人	FINN J PAUL HU PENG HAN FEI		
发明人	FINN, J. PAUL HU, PENG HAN, FEI		
IPC分类号	A61B5/055 A61B5/0205 A61B5/00		
CPC分类号	A61B5/0263 A61B5/055 A61B5/7285 A61B2503/06 G01R33/4822 G01R33/5601 G01R33/5616 G01R33/56325 G01R33/5635 G01R33/5673 A61B5/0402 A61B5/113 A61K49/1818 A61M5/007 A61M16/0003 A61M2016/0027		
代理机构(译)	RICHARDS , JOHN		
优先权	61/990776 2014-05-09 US		
其他公开文献	EP3139833A4		
外部链接	Espacenet		

摘要(译)

公开了3D电影MR血管造影系统和方法，用于在ferumoxytol的稳态血管内分布阶段期间使用。3D电影MRA技术可以改善接受心血管MRI的儿科患者的心脏解剖结构。